

Open peer commentary

## Spatial and temporal relationships between plaques and tangles in Alzheimer-pathology

Bärbel Schönheit, Rosemarie Zarski, Thomas G. Ohm<sup>\*,1</sup>

Department of Clinical Cell and Neurobiology, Institute of Anatomy, Charité, 10098 Berlin, Germany

Received 10 September 2002; received in revised form 29 July 2003; accepted 17 September 2003

### Abstract

One histological hallmark in Alzheimer's disease is the tangle. The other is the plaque. A widely discussed hypothesis is the "amyloid cascade" assuming that tangle formation is a direct consequence of amyloid plaque formation. The aim of this study was to examine plaques and tangles in a highly defined neuronal circuitry in order to determine their detailed spatial and temporal relationships. We investigated serial sections of the whole hippocampal formation of brains with early Braak-stages (0–III) for tangles only, i.e. one case at stage 0, six at stage I, six at stage II, and nine at stage III. Most cases displayed both plaques and tangles. Four cases of stages 0 and I, three cases with stage II, and even one with stage III, however, did not display plaques. In turn, no plaque was found in the absence of tangles. The spatial relationship indicates that plaques lay in the terminal fields of tangle-bearing neurons. Our analysis suggests that tangles either antecede plaques or—less likely—are independently formed.

© 2004 Elsevier Inc. All rights reserved.

**Keywords:** Alzheimer's disease; Amyloid plaques;  $\beta$ A4-peptide; Neurofibrillary tangles; Amyloid cascade hypothesis; Hippocampal formation; Hippocampus; Entorhinal cortex; Time course; Braak staging; Anterograde neurodegeneration; Spatial pattern

### 1. Introduction

In Alzheimer's disease (AD), the main cause of dementia is assumed to result from the progressive loss of synapses and the neuronal degeneration [14,27,42]. The disease's two major histopathological diagnostic hallmarks, the intraneuronally formed neurofibrillary tangle (tangle) and the extracellularly deposited  $\beta$ A4-peptide plaque (plaque), are suspected of inducing the degenerative process. The subject of a long-lasting debate is the question which lesion comes first: plaque or tangle. The interest in the debate is fueled from the strategic dimension of the answer. The first lesion is likely to be closer to the cause of the disease. And knowledge of the underlying mechanisms may help to develop not only treatments of symptoms, but also to find curative means.

Plaques and tangles are abnormal structures that are, however, found in increasing number and with increasing probability in the brains of elderly people. The fact that at autopsy there are many non-demented individuals displaying plaques and tangles in their brains, suggests a long pre-clinical phase

of AD rather than that plaques or tangles are normal during aging and only the different amount is abnormal in AD. In keeping with that view, there are two important findings. First, plaque- and tangle-free brains are found regularly in both the autopsies of elderly subjects who prior to death tested cognitively normal [28,29,36] as well as in large series of routinely autopsied individuals [8,32]. Secondly, since Alois Alzheimer's first description of the disease about a century ago, there has been no published report demonstrating the existence of cases with only old lesions, possibly remaining as so-called ghost-tangles. These "ghost-tangle only" cases, however, ought to be found if there was no inevitable progression towards AD once tangle formation has begun.

Within the cerebral cortex, tangles follow *grosso modo*, a typical pattern of spreading as described by the Braak-classification [7]. This classification strongly correlates to the clinical picture, i.e. the higher the Braak-stage the stronger the cognitive decline [5,6]. In contrast, plaques are distributed in a much more irregular manner. This discrepancy was considered to be an indication for the independence of the two major histological lesions. Others, however, found a close spatial relationship between plaques and tangles as they observed conspicuous accumulations of plaques in terminal fields of defined projection neu-

\* Corresponding author. Tel.: +49-30-450-528202;

fax: +49-30-450-528913.

E-mail address: thomas\_georg.ohm@charite.de (T.G. Ohm).

<sup>1</sup> In memoriam Eva Braak.

rons. This suggested a causal relationship between plaques and tangles [3,4,44]. A widely discussed concept, based upon the assumption that plaque formation antecedes tangle pathology, is the ‘amyloid cascade’ hypothesis [22,23]. According to this hypothesis, plaques occur first (in a more strict version: amyloid plaques, i.e.  $\beta$ -sheeted congo-red stainable A $\beta$ -peptide, showing birifringence under polarized light) and eventually cause tangles in a ‘direct’ way.

In the present study, we tested this hypothesis (and other scenarios) by light-microscopical analysis of the temporal and spatial relationships between plaques and tangles in several well-defined neuronal circuitries of the temporal lobe. The temporal cortex, including the hippocampal formation, has been recognized to be the site of predilection for the pathology of AD. The hippocampal formation, i.e. the entorhinal cortex, subiculum, fascia dentata, and Ammon’s horn with the sectors CA1–CA4 is extremely well-characterized in terms of neuronal connectivity even in higher primates, including humans [16,40,44]. During the early Braak-stages of AD, i.e. stages 0–III, cortical tangles are found only in the hippocampal formation [7]. Since the neurons’ axonal terminals within the hippocampal formation are known, a combined demonstration of plaques and tangles is perfectly suited to address the question of which comes first: plaque or tangle. To that end, we determined the distribution and—in a semi-quantitative way—the amount of tangles and plaques in the different sub-fields of the hippocampal formation in serial sections of autopsy brains with Braak-stages 0–III.

## 2. Materials and methods

Brains from 22 individuals of both sexes (between the ages of 58 and 88 years) were obtained from routine autopsies. Cases with neurological disease and with the diagnosis of dementia were excluded from the study.

The left hemisphere was fixed by immersion in a 4% aqueous solution of formaldehyde. The hippocampal formation and adjoining parahippocampal gyrus were dissected free en bloc, embedded in polyethylene glycol (PEG), and serially cut at 100  $\mu$ m. A series contains the entire anteroposterior extent of the hippocampus. Sections 1, 11, 21, etc. were collected and formed a sub-series which was stained for tangles using the highly sensitive and specific silver-technique of Gallyas. This advanced technique was proven to compete easily with immunocytochemical approaches [10,31]. In addition, a second sub-series was formed using the adjacent sections 2, 12, 22, etc. This sub-series was stained for A $\beta$ -peptide using another type of silver-stain (Campbell-Switzer) which has also been proven to be as sensitive and specific as immunocytochemical approaches [10,31]. A third sub-series consisting of sections 3, 13, 23, etc. was stained with the combination of aldehyde fuchsin and Darrow red in order to facilitate demarcation of hippocampal fields and laminae. Selected sections of a

fourth series were also stained immunocytochemically for  $\beta$ A4-peptide or tangles using standard immunocytochemical protocols as previously published [10]. Briefly, sections were pre-incubated in 70% formic acid for 5 min before un-specific binding sites were blocked by routine techniques. Then the section were incubated overnight with the primary antibody (anti-tau antibodies): 12E8 (1:1000, Athena Neurosciences), AT8 (1:1000, NBS Biological); anti- $\beta$ A4 antibodies: anti-A $\beta$  Clone 6F/3D (Dako, 1:50), G2–10 (1–40) and G2–11 (1–42) (1:20, respectively (kindly provided by Drs. Beyreuther and Hartmann, Heidelberg), and anti-A $\beta$ (1–42) (Boehringer Mannheim, 1:10)). Immunoreaction was visualized by the ABC-method and 4-chloro-1-naphthol as chromogen, coverslipped in Karion F (Merck) and documented. After documentation coverslips were carefully removed and section de-stained by immersion in alcohol. Subsequently, identical sections were silver-stained using the method under consideration (e.g. Campbell-Switzer). In addition, we used 6  $\mu$ m thick paraffin sections from material not being part of the 100  $\mu$ m thick PEG series. Adjacent sections were stained, one with the methenamine silver-stain, the other with the Campbell-Switzer technique. In comparison with sections stained with the relative modern and advanced silver-stains, we did not see a difference to immunostaining in terms of sensitivity or specificity (Fig. 1). This confirms our previous results [10,31] as well as those of others who have made systematical comparisons of various stains [25,30]. Since the silver-stains were less expensive and of comparable quality, we performed our analysis with silver-stained material.

The differentiation of neuropathological stages was carried out as described in detail [7,32]. All cases were classified according to a staging procedure by Braaks denoting both the stage of neurofibrillary tangles (NFT) in roman numerals (0–VI), as well as the plaque stage (in letters 0, A–C). Only cases from Braak-stages 0–III were used in the study. In terms of tangles, there was one case at stage 0 (exemplary showing that at higher age AD-type of pathology is not necessarily present—even in the most vulnerable cortical region of the brain), six at stage I, six at stage II, and nine at stage III. Stages 0–II are never found associated with signs of mild AD, whereas stage III may show the first clinical signs of a beginning dementia as indicated by clinico-histopathological correlations [5,6,18,21]. In our cases, however, clinical reports did not show any indication for a cognitive decline. Cases with cognitive impairment were excluded from our study. The distribution pattern and semi-quantitative estimations of the amount of tangles and plaques were registered for the different sub-fields and layers of the hippocampus as well as for the entorhinal cortex. Since our aim was to analyze the spatial and temporal relationship of plaques and not the relationship between various subtypes of plaques, we did not distinguish between the phenotypes of  $\beta$ A4-deposition, i.e. between pre-amyloid (‘diffuse plaques’), congo-red-positive amyloid plaques, or those formed with abnormal cell processes (‘neuritic

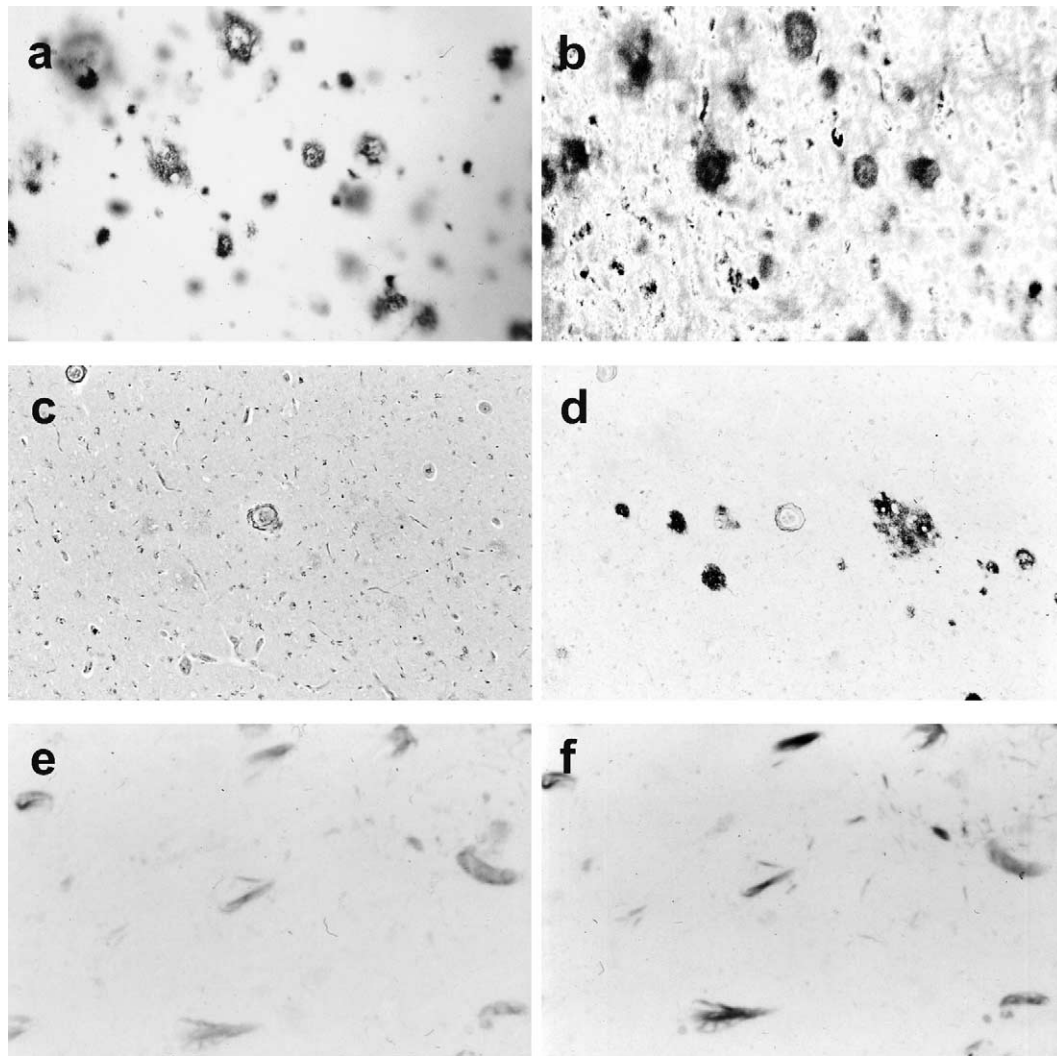


Fig. 1. Tangles and plaques stained by various techniques. (a) Numerous plaques (case 22) marked by antibodies against A $\beta$  (Dako) and visualized by 4-chloro-1-naphthol in 100  $\mu$ m thick PEG-embedded section. (b) Identical section as in (a), 4-chloro-1-naphthol was removed and section subsequently stained by the Campbell-Switzer silver-stain. Note the virtual identical pattern of plaques and that contrast is even better in the silver-stain. Slight differences in the size of plaques is due to the additional handling of tissue during the silver-staining procedure. (c) Methenamine silver-staining of a 6  $\mu$ m thick section showing only weak or no labeling of A $\beta$ -deposits. (d) Adjacent section stained with the Campbell-Switzer silver-stain. Note the superior sensitivity and contrast. (e) Demonstration of tangles by anti-tangle antibodies highlighted by 4-chloro-1-naphthol in a 6  $\mu$ m thick section. (f) Identical section as in (e) after removing of the chromogen 1 and subsequent staining with the Gallyas silver-stain. **Note that the silver-stain demonstrates the very same structures at a higher contrast.** Comparable results can be obtained when comparing the Gallyas technique with other antibodies (e.g. 12E8, which is more robust than AT8 and marking also early stages as does AT8 for example).

plaques'). Furthermore, our stain would have detected any of the subtypes (data not shown). The semi-quantitative estimations of tangles and plaques represent data of all sections examined of the respective sub-field or layer. Subgroups were defined for plaques: 0 = no plaques, few: occasional plaques mostly sized between 50 and 100  $\mu$ m in diameter and not confluent or band-like formation, small amount: conspicuous (mostly >100  $\mu$ m in diameter), often clustered but not confluent, and large amount: numerous deposits, diameter generally >150–200  $\mu$ m, strand of deposits due to confluence of plaques. Subgroups for NFTs were defined: 0 = no lesion, 1–5 = few, 6–10 = small, 11–20 = moderate, and >20 = large number of tangles.

Statistical analysis was performed with the aid of BIAS, a PC-based statistics program [1]. It was assumed that stages represent values on an ordinal scale, as both stages for tangles and plaques were ranked in a way that higher stages were considered to represent more severe stages of the disease-related changes.

### 3. Results

#### 3.1. Tangles

In about one third of the cases examined (7 of 22), tangles were detected in the entorhinal cortex or in one of the

Table 1  
Distribution pattern of tangles in Braak-staged hippocampal formation

**STAGE I**

No.	Brain	Sex	Age	EC			Sub		CA1			CA2	CA3	CA4	FD
	[stage]	[f/m]	[yrs]	Pre $\alpha$	Pre $\beta\gamma$	Pri $\alpha$	Presub	proper	med	int	lat				
1	0/0	f	65												
2	1/0	m	62												
3	1/0	m	60												
4	1/0	m	64												
5	1/A	m	63												
6	1/B	m	59												
7	1/C	f	74												

**STAGE II**

No.	Brain	Sex	Age	EC			Sub		CA1			CA2	CA3	CA4	FD
	[stage]	[f/m]	[yrs]	Pre $\alpha$	Pre $\beta\gamma$	Pri $\alpha$	Presub	proper	med	int	lat				
8	II/0	f	76												
9	II/0	m	85												
10	II/0	m	77												
11	II/A	f	80												
12	II/A	m	58												
13	II/B	m	87												

**STAGE III**

No.	Brain	Sex	Age	EC			Sub		CA1			CA2	CA3	CA4	FD
	[stage]	[f/m]	[yrs]	Pre $\alpha$	Pre $\beta\gamma$	Pri $\alpha$	Presub	proper	med	int	lat				
14	III/0	m	88												
15	III/A	f	81												
16	III/B	f	72												
17	III/B	m	81												
18	III/B	m	79												
19	III/B	f	76												
20	III/C	f	88												
21	III/C	m	85												
22	III/C	m	82												

□ ant. part, post. part      □ head, body, tail

□ no,    ■ few isolated,    ■ small number,    ■ moderate number,    ■ large number of neurofibrillary tangles per region

hippocampal sub-fields, but there were no plaques found anywhere in the hippocampal region. Such cases with no indication for plaques were mainly seen in stages I and II (six cases). Cases with a moderate to severe number of tangles show also a large number of plaques as a rule. On the other hand, one case was seen with a fairly high density of plaques (stage C), but only mild neurofibrillary changes (Braak-stage I). The data is summarized in Table 1 and illustrated in Figs. 2–4.

If tangles occurred, they were found first in the (trans-)entorhinal cortex and then in all of the hippocampal

sub-fields examined except the fascia dentata. We found sector CA1 and the subicular region to be the most vulnerable region and CA2/CA3 to be relatively resistant in terms of neurofibrillary lesion development. Sector CA4 was more vulnerable than CA2/CA3 to tangle formation but less than CA1. This lesion pattern of sub-field changes was observed in all cases, but with different degrees of severity. These area specific changes along the subiculo-dentate axis were seen regularly over the whole length of the hippocampus, however, the border zones between the various sub-fields seem to be particularly susceptible to the

## BRAAK STAGE I

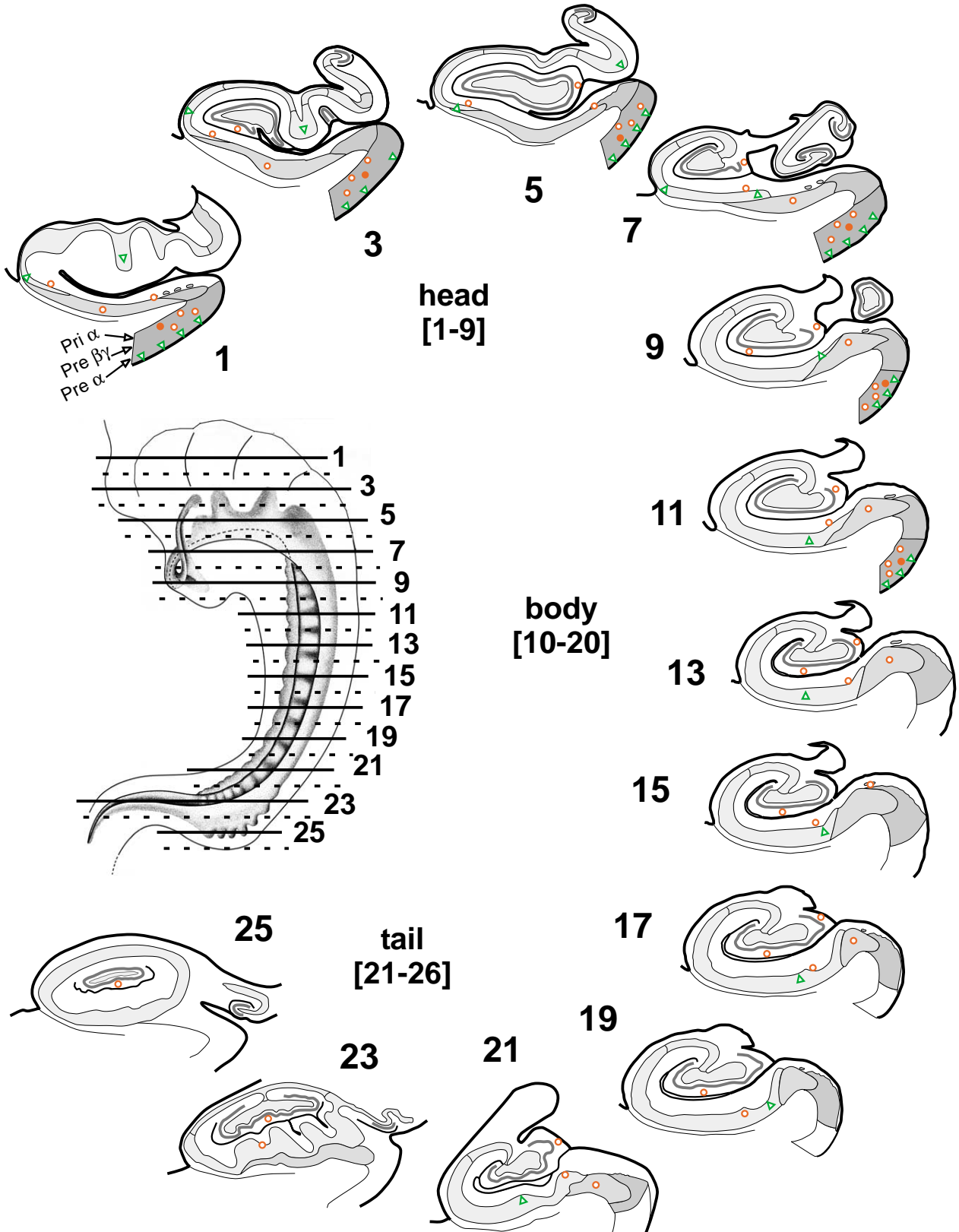


Fig. 2. Tangles and plaques in the whole extension of the hippocampal formation (illustrations in Figs. 2-5 after coronal section diagrams by Duvernoy [16]). ( $\Delta$ ) = 1-10 tangles, ( $\circ$ ) = small number, ( $\bullet$ ) = large number of plaques per region.

### BRAAK STAGE II

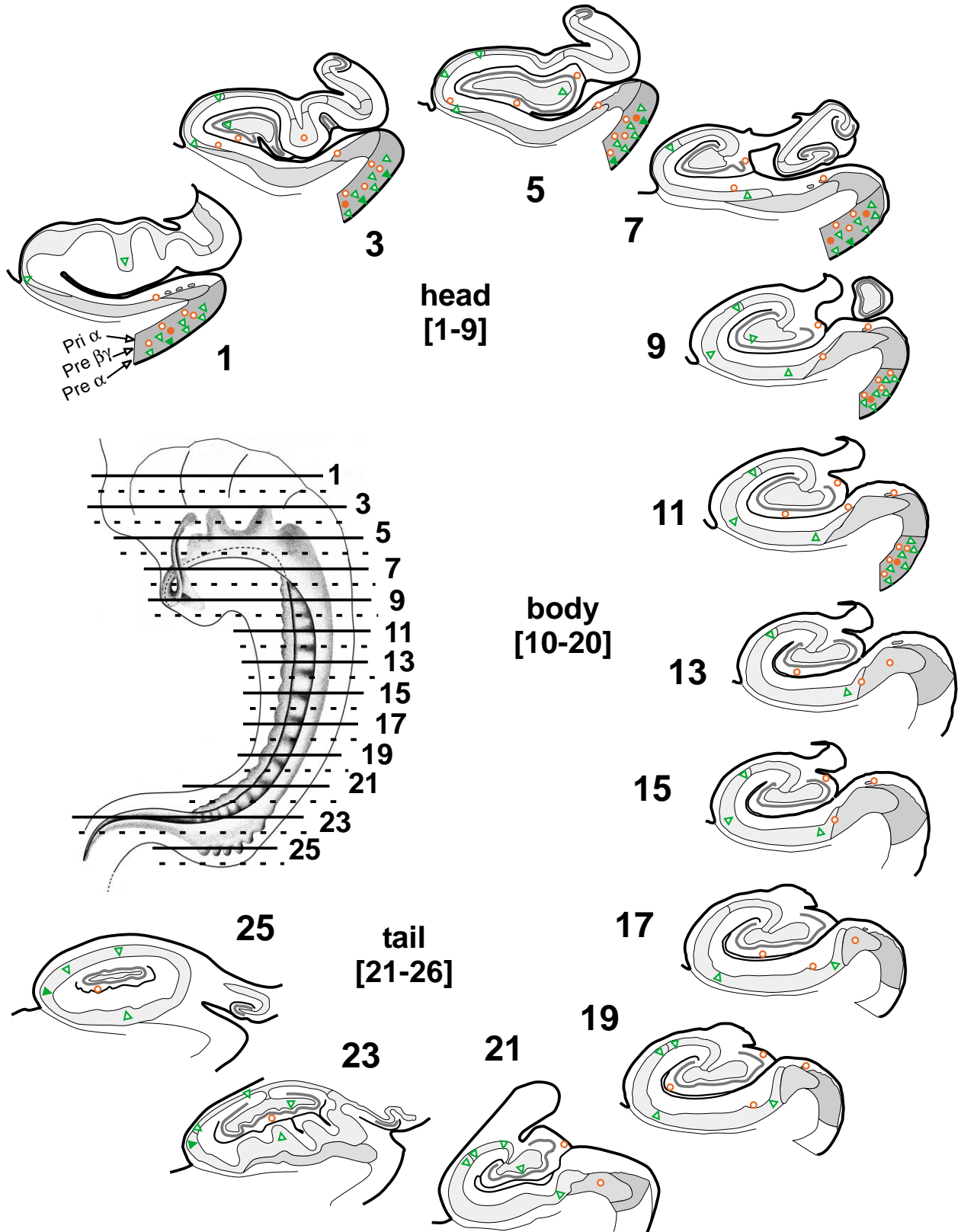


Fig. 3. Tangles and plaques in the whole extension of the hippocampal formation. ( $\Delta$ ) = 1–10 tangles, ( $\blacktriangle$ ) = 11–20 tangles, ( $\circ$ ) = small number, ( $\bullet$ ) = large number of plaques per region.

### BRAAK STAGE III

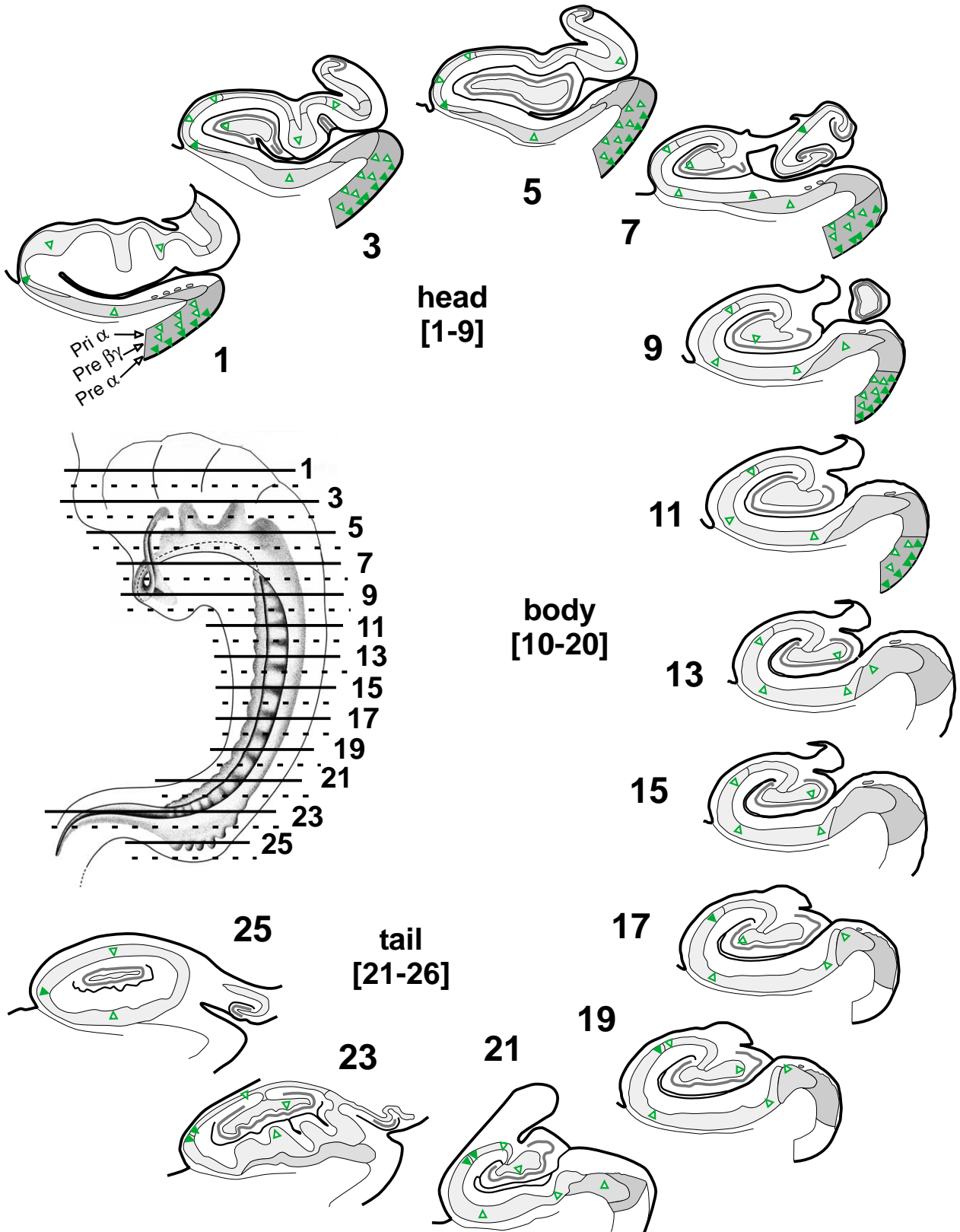


Fig. 4. Tangles in the whole extension of the hippocampal formation. ( $\Delta$ ) = 1-10 tangles, ( $\blacktriangle$ ) = 11-20 tangles, ( $\blacktriangle\blacktriangle$ ) = >20 tangles per region.

AD-related deposits. A higher density of tangle-containing neurons was found in the prosubiculum in the hippocampal head and at the border zone CA1/CA2 in the hippocampal tail. There was no marked gradient along the long axis of the hippocampal formation ( $\chi^2$ -test, not significant).

In the Braak-stage I, neurofibrillary changes were restricted to the Pre- $\alpha$ -layer of the entorhinal cortex and the medial part of CA1, if at all. This initially affected part of CA1 is frequently termed the “prosubiculum.” From here the tangle formation spread slowly towards CA2. The density of affected neurons was very low, about 1–5 tangles per region. Two cases also revealed a few isolated tangles in the layer Pre- $\beta$  of entorhinal cortex.

In the Braak-stage II, there was a small increase in tangle density in the layer Pre- $\alpha$  of the entorhinal cortex (about 10 tangles per island), and isolated tangles were generally found in the deeper entorhinal layer Pre- $\beta$  and in the whole hippocampal sub-field CA1, its lateral, intermediate, and medial part. Occasionally, tangles appeared also in the layer Pri- $\alpha$  of the entorhinal cortex and in the hippocampal sub-field CA4. However, the prominent feature of stages I and II, accordingly, is the pronounced entorhinal involvement.

The Braak-stage III was characterized by a moderate to severe involvement of the entorhinal layer Pre- $\alpha$ . In the layers Pre- $\beta$  and Pri- $\alpha$ , a few tangles were generally encountered. The hippocampal region showed a moderate involvement of CA1 and a mild involvement of CA4 with only few isolated tangles in nerve cells located close to the plexiform layer of the fascia dentata. The part of CA1 which is particularly susceptible to develop neurofibrillary changes, the prosubiculum, showed the highest numeric density of tangle-bearing neurons in the head of the hippocampus, in line with a slight head-to-tail gradient with respect to the numeric density of tangles. The most striking feature was the tangle pronounced borderline CA1/CA2 and the appearance of tangles in CA3 in the hippocampal tail, the end of the hippocampus. This was also seen in a diminished intensity at Braak-stage II.

### 3.2. Plaques

Both the amount and density of plaques varied regionally within the hippocampal formation of a given case, but also between cases. It turned out that four cases of stages 0 and I, three of the six cases of stage II, and even one of the nine cases of stage III displayed no plaques. If plaque-formation occurred, the plaques were restricted to the entorhinal cortex layers Pre- $\beta$ , Pre- $\gamma$ , and Pri- $\alpha$ , the subicular region, CA1, and the fascia dentata. First to be affected are the entorhinal cortex and the subicular region; the fascia dentata and the CA1-region develop amyloid deposits later. A plaque-pronounced region is the border zone CA1/subiculum where there are deposits not only in the superficial non-pyramidal layer, but also in the pyramidal layer itself. In all of the 22 cases examined cases, plaques never appeared before tangles appeared. As for tangles, there was no significant gradient seen along the long axis of the hippocampal formation.

Stage C was characterized by a more constant distribution pattern of plaques: compared with the basal isocortical areas, the hippocampal formation is only mildly involved. In the subiculum and adjoining sector, CA1, the plaques formed a band of small and densely packed deposits above the pyramidal cell layer which itself contains a different number of larger spherical deposits. A second band of deposits is formed in the fascia dentata, exactly in the middle third of the molecular layer. The parvocellular layer of presubiculum shows a characteristic picture of finely structured, diffusely distributed A $\beta$ -peptide. This plaque pattern can also be seen in the stage B, however the amount of deposits was generally smaller. In the one case with tangle stage I but plaque stage C, a higher number of plaques were observed than in the stages III/C (three cases). Of the stage A cases, there was one case at Braak-stage I, two cases at stage II, and one case at stage III.

A summary of the detailed distribution pattern and the semi-quantitative analysis of the numeric density of plaques is given in Table 2 and illustrated in Figs. 2, 3 and 5.

## 4. Discussion

Using the entorhinal-hippocampal system, we were able to analyze both the temporal and the spatial development of AD-related plaques and tangles. Our study reveals that in very early stages of the disease tangles develop before plaques (in 7 out of 21 cases). In none of the cases, plaques occurred before tangles. The finding is schematically summarized in Fig. 5 providing also the anatomical structure of the examined neuronal circuits. Our findings are in agreement with the suggestion of Braaks that initial neurofibrillary changes develop in the absence of amyloid deposits [9]. Interestingly, a study by Price et al.—though not analyzing hippocampal projections in our detail—found similar results [35]. In their preparations of some 20 cases practically corresponding to the low Braak-stages which we have considered, they found tangles in entorhinal cortex (the layers were not analyzed separately) of nine cases, but no plaques in the fascia dentata. In none of their cases was plaque formation found in the dentate gyrus without tangle formation in the entorhinal cortex.

Our proof that tangles antecede plaques was made possible by (i) examination of several well-characterized neuronal circuitries for AD-related changes in both the dendritic field/soma of a neuron and the terminal field of its axonal projection using (ii) serial sections of cases with early, i.e. circumscribed stages of AD-related pathology. Our finding is, on one hand, in keeping with previous suggestions that tangles may temporally develop before or independent from plaques [7,35]. In these analyses of large areas of cortical and subcortical gray matter for the prevalence of both plaques and tangles, cases were found that displayed small numbers of tangles but no plaques. These studies, however, were not able to rule out the major objection that the



Table 2  
Distribution pattern of plaques in Braak-staged hippocampal formation

STAGE I															
No.	Brain [stage]	Sex [f/m]	Age [yrs]	EC			Sub		CA1			CA2	CA3	CA4	FD
				Pre $\alpha$	Pre $\beta\gamma$	Pri $\alpha$	Presub	proper	med	int	lat				
1	0/0	f	65												
2	1/0	m	62												
3	1/0	m	60												
4	1/0	m	64												
5	1/A	m	63												
6	1/B	m	59												
7	1/C	f	74												

STAGE II															
No.	Brain [stage]	Sex [f/m]	Age [yrs]	EC			Sub		CA1			CA2	CA3	CA4	FD
				Pre $\alpha$	Pre $\beta\gamma$	Pri $\alpha$	Presub	proper	med	int	lat				
8	II/0	f	76												
9	II/0	m	85												
10	II/0	m	77												
11	II/A	f	80												
12	II/A	m	58												
13	II/B	m	87												

STAGE III															
No.	Brain [stage]	Sex [f/m]	Age [yrs]	EC			Sub		CA1			CA2	CA3	CA4	FD
				Pre $\alpha$	Pre $\beta\gamma$	Pri $\alpha$	Presub	proper	med	int	lat				
14	III/0	m	88												
15	III/A	f	81												
16	III/B	f	72												
17	III/B	m	81												
18	III/B	m	79												
19	III/B	f	76												
20	III/C	f	88												
21	III/C	m	85												
22	III/C	m	82												

ant. part, post. part
  head, body, tail

no,
  few isolated,
  small number,
  large number of  $\beta$ A4 - deposits per region

investigators might have missed plaques, as the terminal fields of the neurons under investigation were not (or not to their necessary extent) seen in the examined sections. On the other hand, a spatial relationship between the presence of plaques in the axon's terminal field and occurrence of tangles in the neurons of origin was also suggested previously [2-4,7]. In these studies on fully developed AD-cases, however, the temporal relationship between plaques and tangles is only hardly to examine because too many interconnected brain regions have to be taken into consideration at the same time. This made it difficult to decide whether a given plaque is temporally related to a given projection.

In our study, this problem was circumvented by restricting the analysis to anatomically well-defined projections being already involved in early stages of AD-pathology. Further, we have taken care to avoid two other potentially critical methodological limitations. First, one might argue that our silver-stains were not sensitive enough to detect all  $\beta$ A4-deposits when compared to other techniques. This, however, is unlikely, as several studies have already been performed that clearly show that both silver-stains, the Gallyas for tangles and the Campbell-Switzer for  $\beta$ A4-peptide, were as sensitive and specific as immunocytochemical stains [10,25,30,31]. One might still think, however, that our

### BRAAK STAGE III

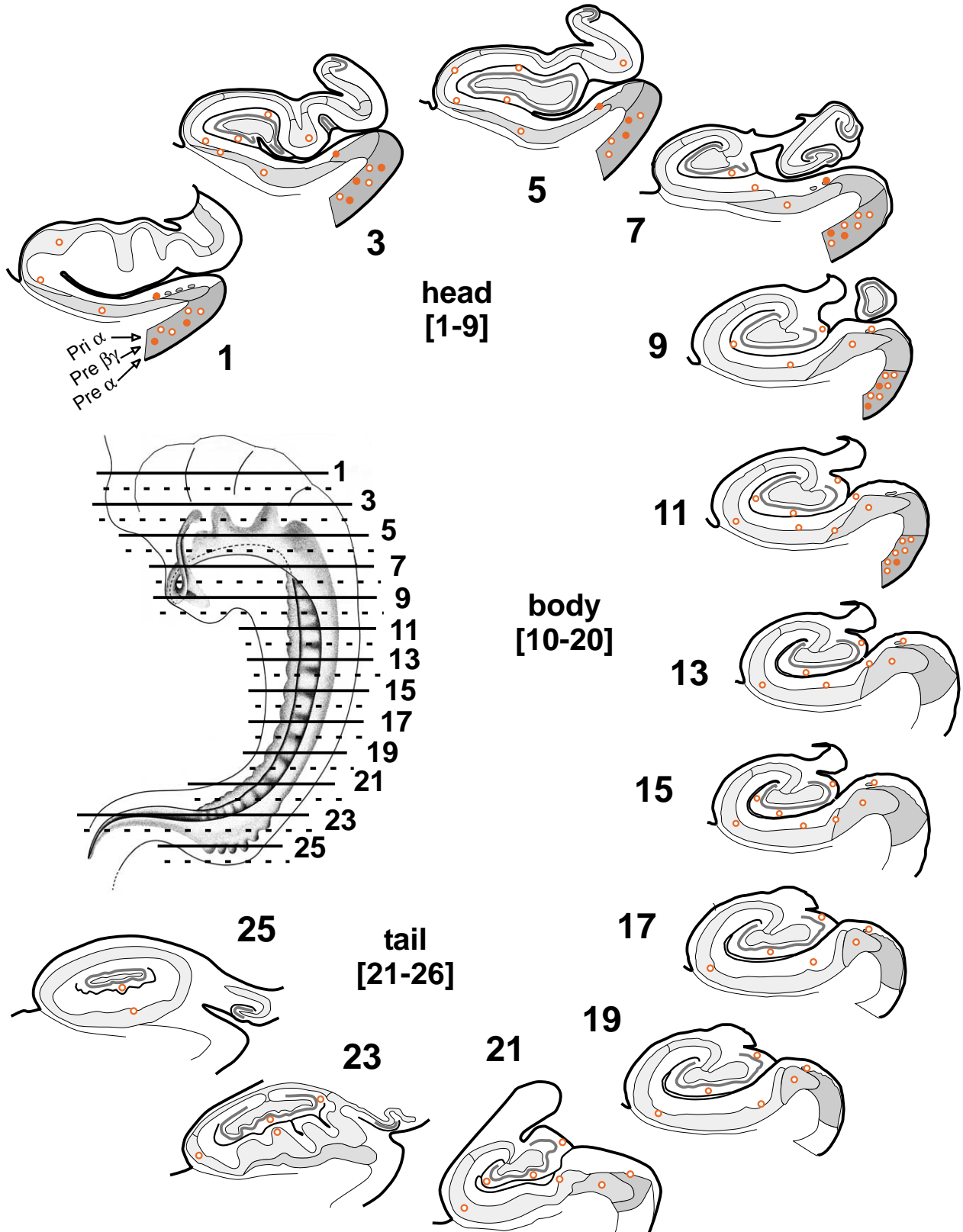


Fig. 5. Plaques in the whole extension of the hippocampal formation. (○) = few and/or small number, (●) = large number of plaques per region.

examined cases, especially those with few tangles, may behave slightly different than more advanced AD cases. Then, although in general the stains were of high definition, we might have missed pathological lesions. In order to rule out this and related criticisms [15], we examined selected consecutive sections of our series with immunocytochemical stains and found a virtually identical degree of detection as seen in our silver-stained sections (Fig. 1). This is in line with previous data comparing various stains and finding Gallyas silver-staining for tangles superior to anti-PHF or anti-tau immunocytochemistry [15]. Comparing to anti-A $\beta$  immuno-staining the methenamine silver-staining was previously found less sensitive, whereas the Campbell-Switzer silver-stain was not studied by He et al. [24]. When counting classical plaques (no diffuse and sub-pial plaques) in a comparison of various stains Rosenwald et al. found the Campbell-Switzer technique to be slightly more sensitive than A $\beta$ -immunohistochemistry [37]. As already demonstrated by Braak and Braak [11], we saw a virtually identical staining result between anti-A $\beta$  immunocytochemistry and the Campbell-Switzer stain including in the demonstration of diffuse plaques and sub-pial A $\beta$ -deposits. We also found that the Campbell-Switzer stain outranged the methenamine silver-stain. Taken together, the previous data [10,11,24,25,30,31,37] were confirmed and provided another independent prove that the Gallyas and the Campbell-Switzer stains are as sensitive and selective as immunocytochemical techniques to visualize plaques and tangles.

Secondly, another crucial argument has already been formulated: one might overlook plaques when the section under consideration does not contain the axonal terminal field of the tangle-bearing neuron. In order to avoid this, we analyzed serial sections of a well-defined neuronal circuitry, the hippocampal formation. In order to not make it more tedious than necessary, we examined every tenth section for plaques and tangles; therefore maximal gap width between the consecutive sections was 1000  $\mu\text{m}$ . Even in the early stages of AD, plaques are relatively large objects although of varying size. Typical size of a plaque is about 200  $\mu\text{m}$ . Thus, the chance to detect a plaque is  $P = 0.2$ , i.e. 20%, when analyzing only 1 section out of 10. In turn, the probability to have missed a plaque is  $P = 0.8$  or 80%. This value would be essentially the same for the whole series (e.g. when examining every tenth sections out of 300 sections (sections 1, 11, 21, 31, . . . , 291)) if plaques occurred at highly regular spatial intervals. From all that we know—including the results of the present study—there is no such regular spacing between plaques, i.e. each plaque is separated from its neighbor by for example, 1000  $\mu\text{m}$ . Furthermore, there is no marked gradient in the numeric density of plaques found along the longitudinal axis of the hippocampus, i.e. the probability to detect a plaque at the more anterior pole of the hippocampus is similar to that at the more posterior pole. Together this implies that the probability to have potentially overlooked plaque formation somewhere in the hippocampal formation is extremely low: The total prob-

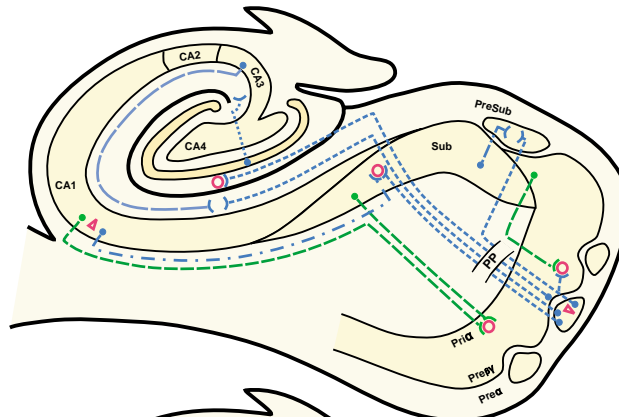
ability to have overlooked an existing plaque is calculated as  $P_{\text{total}} = P_{\text{section 1}} \times P_{\text{section 11}} \times P_{\text{section 21}} \times P_{\text{section 31}} \times \dots \times P_{\text{section 291}} = 0.8 \times 0.8 \times 0.8 \times \dots \times 0.8 = 0.00124$ . As our series generally consist of more than 300 sections per case, the real probability is still lower than about 0.1% to have miss-classified a case as “plaque-free.” It is much more likely to have missed a tangle (usually about the size of a normal pyramidal cell soma, i.e. 30  $\mu\text{m}$  of diameter). Also so-called ‘diffuse tangles’ (i.e. conformationally altered tau lacking fibrillar organization) may be missed in considerable number [43]. The underestimation of tau-pathology, however, is much less problematic as it would only result in a further increase of plaque-free but tangle-positive cases, i.e. more than 7 out of 22 cases as determined.

In order to facilitate the interpretation of our findings one should first recall the putative spatial and temporal relationships between plaques and tangles. One major class of relationships is given when plaques and tangles may cause each other. Then the two entities should have specific spatial relationships. Either they induce each other locally, i.e. as neighbors (then tangles should be found predominantly within plaques or in close vicinity) or in neuroanatomical relation (plaques in the terminal field of a tangle-bearing projection neuron). In this case, it may either be a retrograde process (plaques in the terminal field at first and tangle-formation in the respective projection neuron’s soma later) or an anterograde process (i.e. tangle formation in the soma and thereafter the deposition of plaques in its axon’s terminal field). The other possibility is that plaques and tangles are formed independently. This may mean: there is no spatial relationship between plaques and tangles, or, plaques and tangles have tendencies to develop differentially in given brain areas. In this case an observed spatial pattern is not due to an interaction between the two lesion types but due to other factors modulating the local susceptibility for each of the pathological entities differentially but independently.

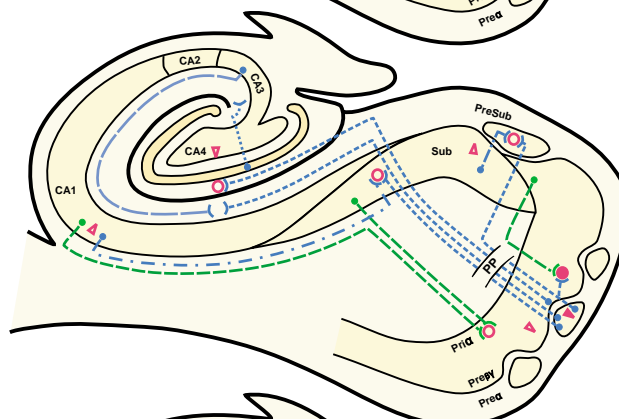
A widely discussed causative relationship between plaques and tangles is laid out in the ‘amyloid cascade’ hypothesis. As originally laid out [22,23] the concept assumes that the extracellular plaques composed by  $\beta\text{A4}$ -amyloid (not of soluble  $\beta\text{A4}$ -peptide) are the primary cause of Alzheimer’s pathology and tangle formation follows as a direct result of this deposition. Our findings do not support this hypothesis. In one third of our cases tangles were seen but no plaques. And in none of the cases plaques were seen without the presence of tangles—as would have been to be expected if the ‘amyloid cascade’ hypothesis was true. Even the deposition of extracellular  $\beta\text{A4}$ -peptide (so-called pre-amyloid plaques) does not precede tangle formation, as our stain is able to detect both forms of  $\beta\text{A4}$ . It may, however, be that the formation of  $\beta\text{A4}$ -peptide has taken place which has not aggregated to light-microscopically detectable plaques, including diffuse plaques. This issue—as well as the aspect of tau-aggregation before light-microscopical detectability in form of tangles—has to be addressed by electron microscopy. This, however, will be a tedious task

### RELATIONSHIP OF PLAQUES AND TANGLES

**STAGE I**



**STAGE II**



**STAGE III**

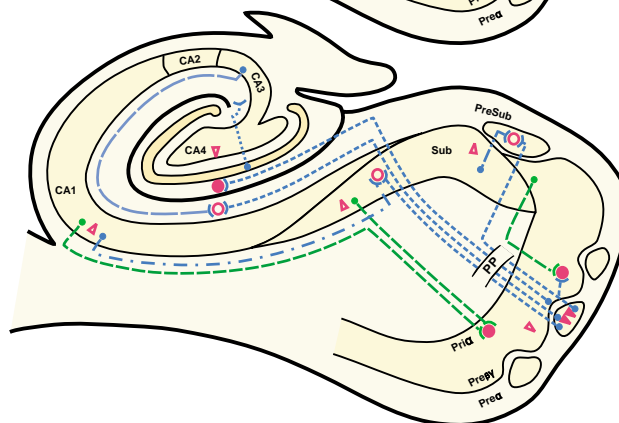


Fig. 6. Scheme of the entorhinal-hippocampal connections under consideration and the temporo-spatial findings regarding plaques and tangles. Neurons of origin of a given projection are symbolized by a dot, the axonal projection by various lines (coding within the figure), and the termination zone is represented by --< in the layer and sub-field of the hippocampus. For sake of clarity the plaques (open (few) and filled (many) circles) and tangles (open (few) and filled (many) triangles) were depicted only in relation to the principal connectivity. Please note that this scheme summarizes the data from various cases and section levels. For a detailed topography of plaques and tangles please refer to Tables 1 and 2 and Figs. 1–4. Plaques may occur in overlapping of termination zones of different axonal projections under consideration. This is indicated by a plaque between the axonal termination zones. As a consequence for a ‘simple’ retrograde degeneration hypothesis neurons of origin of both projections should have tangles in later stages. In light of an anterograde degeneration concept, it would be sufficient to have tangles only in the neurons of one of the projections under consideration. EC = entorhinal cortex, Pre-α, -β, -γ = lamina principalis externa alpha, beta, gamma, Pri-α = lamina principalis interna alpha, FD = fascia dentata, CA1–CA3 = sector 1–3 of cornu ammonis, sub = subiculum, presub = presubiculum.

when considering serial sections along the whole hippocampal formation. One should keep in mind, that the presented data do not exclude the possibility that soluble  $\beta$ A4-peptide and/or miss-metabolism of APP processing can significantly contribute to the development of AD.

Our data are in line with the concept that plaques develop in relation to the axon terminals of tangle bearing neurons (see Fig. 6) [44]. This has been suggested previously. Armstrong et al. [3,4] examined the distribution of tangles and plaques in the hippocampal gyrus and parahippocampal gyrus in Alzheimer's disease. Their conclusions that the higher numeric density of plaques in CA1 may reflect a corresponding increase in plaque numbers in the subiculum, or that a low incidence of tangles in the fascia dentata may be related to the low numeric density of plaques in CA3, correspond with our observations. In the molecular layer of the fascia dentata, the plaques have occupied the terminal zone of the perforant path which is formed by axons of neurons of the entorhinal cortex. At the stage of plaque formation, these projection neurons have since long undergone tangle formation. In line with an anterograde axonal release of A $\beta$ -peptide is the fact that plaques in the perforant path terminal zone are not seen anymore when, in late stages of AD, the neurons giving rise to the perforant path have died [12]. Obviously, the previously existing plaques must have been cleared and the lack of perforant path axons avoids further plaque formation. The concept of an anterograde degeneration can also explain why there are plaques in the cerebellum and no plaques in the mossy fiber system of the hippocampus. Granule cells of the fascia dentata virtually never develop tangles perhaps due to a specific splicing of the tau gene eventually resulting in the lack of the 4-repeat tau and a difference in tau phosphorylation [20]. Even in severe cases with AD pathology, there is no significantly emphasized plaque formation in the mossy fiber zone as should occur if plaques were first and tangles develop as a direct result of a retrograde process. Plaques were found in the cerebellum—in particular in more severe AD cases—whereas there were no tangles even in very severe cases. The plaques may be formed by release of A $\beta$  from incoming axons originating from tangle-bearing neurons in sub-cortical projection system. For example, the noradrenergic nucleus coeruleus projects into the cerebellum. Also some plaques underneath the pial surface may result from axonal branches of the noradrenergic system which forms a widespread dense fiber plexus in layer I of the isocortex functionally related to control of local blood flow [26]. The noradrenergic system is forming tangles very early, i.e. at cortical Braak-stage I or II [13]. Other sub-cortical projection systems are forming tangles as early as the noradrenergic system and are known to project into the cerebellum as well (e.g. the serotonergic oral raphe nuclei [38] or the cholinergic projection arising from the nucleus basalis of Meynert [39]). They may likewise contribute to isocortical plaque formation before severe tangle formation in the hippocampus. The fact that tangles may be found first within the allocortical hippocampal

formation, i.e. the Pre- $\alpha$  neurons which project to the hippocampus, whereas plaques are found first in some isocortical areas which receive entorhinal input from the (deeper) pri-layers forming tangles later than pre-layer neurons, was previously considered to argue in favor of an independent process. We presume that these early plaques are found in the projection fields of some of the widely arborising axons of these and other early altered sub-cortical projection systems. The suggested scenario regarding the temporal and spatial relationship of plaque and tangle, however, does not exclude the possibility that both pathogenic pathways, i.e. that for plaques and for tangles, may interact [17,36,41].

In a concept in which tangles are considered to be first and plaques second an explanation has to be offered for the observation that a minor proportion of AD cases are caused by mutations such as in the gene of the precursor of  $\beta$ A4, i.e. the APP gene. The fact that the APP mutation predicts AD is widely considered to support unequivocally the 'amyloid cascade' hypothesis. In these cases numerous tangles are formed as well. It remains, however, to be shown that the tangles are really formed later than the plaques as predicted for example by the 'amyloid cascade' hypothesis. Presumed plaques were really proven to be found earlier than tangles, then it still may have two interpretations in light of our data on sporadic cases. Firstly, in individuals with a mutation in the APP gene a mechanism different to sporadic cases may first lead to plaques and subsequently (e.g. in causal terms of the 'amyloid cascade' hypothesis) to tangles. It seems to us, however, a second interpretation more likely because it does not require the assumption of a different mechanism and is furthermore in line with already known findings regarding sporadic cases. This second interpretation also assumes that tangles are formed independently from  $\beta$ A4-amyloid (i.e. they are not caused by  $\beta$ A4-amyloid in sense of the 'amyloid cascade' hypothesis). It is, however, considered that an increased production of  $\beta$ A4-peptide may lead to an accelerated speed of tangle formation [19,34]. Then the following scenario may unify the various findings. The metabolic process underlying the formation of tangles is, due to the APP mutation, accelerated as is the plaque formation. However, acceleration of plaque formation is stronger than acceleration of tangle formation, eventually resulting in an earlier deposition of  $\beta$ A4-peptide than of tau aggregation (both in terms of light-microscopical detection). The substantial tangle formation in the cases with an APP-mutation may then be result of an interaction in which amyloid has accelerated an already ongoing process of tau aggregation rather than to cause this process. Interestingly, this role for  $\beta$ A4-peptide (as an accelerator for tangle formation) is supported by several recent findings [19,33,45].

## Acknowledgments

We appreciate the financial support of the Deutsche Forschungsgemeinschaft (Oh48/1-4, SFB507 TP C2) and

the Forschungskommission der Charité. Expert secretarial help was provided by Ms. U. Grallert and illustrations were perfectly styled by Ms. Mansfeld and Ms. Lewandowski. We thank Prof. Heiko Braak for allowing the examination of some serially cut cases of his brain collection.

## References

- [1] Ackermann H. BIAS—a programme package for biometrical analysis of samples. *Comp Stat* 1991;11:223–4.
- [2] Armstrong RA. The relationship between senile plaques, neurofibrillary tangles and amyloid (A4) deposits in Alzheimer's disease—a principal components analysis. *Neurosci Res Commun* 1991;9:91–7.
- [3] Armstrong RA, Myers D, Smith CUM. The distribution of senile plaques, neurofibrillary tangles and beta/A4 deposits in the hippocampus in Alzheimer's disease. *Neurosci Res Commun* 1992;10:87–94.
- [4] Armstrong RA, Myers D, Smith CUM, Cairns N, Luthert PJ. Alzheimer's disease—the relationship between the density of senile plaques, neurofibrillary tangles and A4 protein in human patients. *Neurosci Lett* 1991;123:141–3.
- [5] Baner C, Braak H, Fischer P, Jellinger KA. Neuropathological staging of Alzheimer lesions and intellectual status in Alzheimer's and Parkinson's disease patients. *Neurosci Lett* 1993;162(1/2):179–82.
- [6] Braak H, Duyckaerts C, Braak E, Piette F. Neuropathological staging of Alzheimer-related changes correlates with psychometrically assessed intellectual status. In: *Alzheimer's disease: advances in clinical and basic research*; 1993.
- [7] Braak H, Braak E. Neuropathological staging of Alzheimer-related changes. *Acta Neuropathol (Berl)* 1991;82(4):239–59.
- [8] Braak H, Braak E. Frequency of stages of Alzheimer-related lesions in different age categories. *Neurobiol Aging* 1997;18(4):351–7.
- [9] Braak H, Braak E, Bohl J, Reintjes R. Age, neurofibrillary changes, A beta-amyloid and the onset of Alzheimer's disease. *Neurosci Lett* 1996;210(2):87–90.
- [10] Braak H, Braak E, Ohm TG, Bohl J. Alzheimer's disease: mismatch between amyloid plaques and neuritic plaques. *Neurosci Lett* 1989;103:24–8.
- [11] Braak H, Braak E. Author's response to commentaries. *Neurobiol Aging* 1997;18(4):389–92.
- [12] Braak H, Braak E. Temporal sequence of Alzheimer's disease-related pathology. In: Peters, Morrison, editors. *Cerebral cortex*. New York: Kluwer Academic/Plenum Publishers; 1999. p. 475–512.
- [13] Busch C, Bohl J, Ohm TG. Spatial, temporal and numeric analysis of Alzheimer changes in the nucleus coeruleus. *Neurobiol Aging* 1997;18(4):401–6.
- [14] Cras P, Smith MA, Richey PL, Siedlak SL, Mulvihill P, Perry G. Extracellular neurofibrillary tangles reflect neuronal loss and provide further evidence of extensive protein cross-linking in Alzheimer disease. *Acta Neuropathol (Berl)* 1995;89(4):291–5.
- [15] Cummings BJ. Plaques and tangles: searching for primary events in a forest of data. *Neurobiol Aging* 1997;18(4):358–62.
- [16] Duvernoy HM. *The human hippocampus. An atlas of applied anatomy*. München: J.F. Bergmann; 1998.
- [17] Giaccone G, Pedrotti B, Migheli A, Verga L, Perez J, Racagni G, et al. Beta PP and Tau interaction. A possible link between amyloid and neurofibrillary tangles in Alzheimer's disease. *Am J Pathol* 1996;148(1):79–87.
- [18] Gold G, Bouras C, Kovari E, Canuto A, Glaria BG, Malky A, et al. Clinical validity of Braak neuropathological staging in the oldest-old. *Acta Neuropathol (Berl)* 2000;99(5):579–82.
- [19] Gotz J, Chen F, Van Dorpe J, Nitsch RM. Formation of neurofibrillary tangles in P3011 tau transgenic mice induced by Abeta 42 fibrils. *Science* 2001;293(5534):1491–5.
- [20] Gotz J, Nitsch RM. Compartmentalized tau hyperphosphorylation and increased levels of kinases in transgenic mice. *NeuroReport* 2001;12(9):2007–16.
- [21] Grober E, Dickson D, Sliwinski MJ, Buschke H, Katz M, Crystal H, et al. Memory and mental status correlates of modified Braak staging. *Neurobiol Aging* 1999;20(6):573–9.
- [22] Hardy JA. An anatomical cascade hypothesis for Alzheimer's disease. *Trends Neurosci* 1992;15:200–1.
- [23] Hardy JA, Higgins GA. Alzheimer's disease: the amyloid cascade hypothesis. *Science* 1992;256(5054):184–5.
- [24] He Y, Duyckaerts C, Delaere P, Piette F, Hauw JJ. Alzheimer's lesions labelled by anti-ubiquitin antibodies: comparison with other staining techniques. A study of 15 cases with graded intellectual status in ageing and Alzheimer's disease. *Neuropathol Appl Neurobiol* 1993;19(4):364–71.
- [25] Lamy C, Duyckaerts C, Delaere P, Payan C, Fermanian J, Poulain V, et al. Comparison of 7 staining methods for senile plaques and neurofibrillary tangles in a prospective series of 15 elderly patients. *Neuropathol Appl Neurobiol* 1989;15:563–78.
- [26] Magistretti PJ, Morrison JH. Noradrenaline- and vasoactive intestinal peptide-containing neuronal systems in neocortex: functional convergence with contrasting morphology. *Neuroscience* 1988;24:367–78.
- [27] Masliah E, Terry R. The role of synaptic proteins in the pathogenesis of disorders of the central nervous system. *Brain Pathol* 1993;3(1):77–85.
- [28] Morris JC. The challenge of characterizing normal brain aging in relation to Alzheimer's disease. *Neurobiol Aging* 1997;18(4):388–9.
- [29] Morris JC, McKeel DW, Storandt M, Rubin EH, Price JL, Grant EA, et al. Very mild Alzheimer's disease—informant-based clinical, psychometric, and pathologic distinction from normal aging. *Neurology* 1991;41:469–78.
- [30] Morris JC, Storandt M, McKeel DW, Rubin EH, Price JL, Grant EA, et al. Cerebral amyloid deposition and diffuse plaques in “normal” aging: evidence for presymptomatic and very mild Alzheimer's disease. *Neurology* 1996;46(3):707–19.
- [31] Ohm TG, Braak E, Braak H. A competition between silver-stain and immunocytochemistry. *Neural Transm (P-D Sect)* 1989;1:111.
- [32] Ohm TG, Muller H, Braak H, Bohl J. Close-meshed prevalence rates of different stages as a tool to uncover the rate of Alzheimer's disease-related neurofibrillary changes. *Neuroscience* 1995;64(1):209–17.
- [33] Pignio G, Pelsman A, Mori H, Busciglio J. Presenilin-1 mutations reduce cytoskeletal association, deregulate neurite growth, and potentiate neuronal dystrophy and tau phosphorylation. *J Neurosci* 2001;21(3):834–42.
- [34] Price JL. Tangles and plaques in healthy aging and Alzheimer's disease: independence or interaction. *Semin Neurosci* 1994;3(95–402):402.
- [35] Price JL, Davis PB, Morris JC, White DL. The distribution of tangles, plaques and related immunohistochemical markers in healthy aging and Alzheimer's disease. *Neurobiol Aging* 1991;12(4):295–312.
- [36] Price JL, Morris JC. Tangles and plaques in nondemented aging and “preclinical” Alzheimer's disease. *Ann Neurol* 1999;45(3):358–68.
- [37] Rosenwald A, Reusche E, Ogomori K, Teichert HM. Comparison of silver-stainings and immunohistology for the detection of neurofibrillary tangles and extracellular cerebral amyloid in paraffin sections. *Acta Neuropathol (Berl)* 1993;86(2):182–6.
- [38] Rub U, Del Tredici K, Schultz C, Thal DR, Braak E, Braak H. The evolution of Alzheimer's disease-related cytoskeletal pathology in the human raphe nuclei. *Neuropathol Appl Neurobiol* 2000;26(6):553–67.
- [39] Sassin I, Schultz C, Thal DR, Rub U, Arai K, Braak E, et al. Evolution of Alzheimer's disease-related cytoskeletal changes in the basal nucleus of Meynert. *Acta Neuropathol (Berl)* 2000;100(3):259–69.

- [40] Seress L. Interspecies comparison of the hippocampal formation shows increased emphasis on the regio superior in the Ammon's horn of the human brain. *J Hirnforsch* 1988;29(3):335–40.
- [41] Smith MA, Siedlak SL, Richey PL, Mulvihill P, Ghiso J, Frangione B, et al. Tau protein directly interacts with the amyloid beta-protein precursor: implications for Alzheimer's disease. *Nat Med* 1995;1(4):365–9.
- [42] Terry RD, Masliah E, Salmon DP, Butters N, DeTeresa R, Hill R, et al. Physical basis of cognitive alterations in Alzheimer's disease—synapse loss is the major correlate of cognitive impairment. *Ann Neurol* 1991;30:572–80.
- [43] Uboga NV, Price JL. Formation of diffuse and fibrillar tangles in aging and early Alzheimer's disease. *Neurobiol Aging* 2000;21(1):1–10.
- [44] van Hoesen GW, Hyman BT. Hippocampal formation: anatomy and the patterns of pathology in Alzheimer's disease. *Prog Brain Res* 1990;83:445–57.
- [45] Wegiel J, Bobinski M, Tarnawski M, Dziewiatkowski J, Popovitch E, Miller DC, et al. Fibrillar amyloid-beta affects neurofibrillary changes but only in neurons already involved in neurofibrillary degeneration. *Acta Neuropathol (Berl)* 2001;101(6):585–90.