

Application of Silver Degeneration Stains for Neurotoxicity Testing

ROBERT C. SWITZER III

NeuroScience Associates, Knoxville, Tennessee 37922

ABSTRACT

Silver staining procedures have been used in numerous ways to render a variety of physical and biological features visible. In biological tissue, histologic protocols use silver to visualize diverse structures or features, such as reticulin, melanin, fungi, chromosome bands, nucleolar organizing regions, and different features in the nervous system. A comparison of the specific steps in these protocols indicates that the silver is "directed" to stain any given feature by the type of fixation, the pretreatment ("mordanting"), the composition of the silver-containing solution(s), and the form of development (reduction). Since the mechanisms of staining have not been understood historically (nor are they now), each method was developed by trial and error. Keystone methods such as those of Bodian and Bielschowsky exploit the nervous system's affinity for silver (argyrophilia). The beginning of a new era in brain research came with the recognition that distinct silver-impregnated morphologic changes occurring in damaged axons could be used for tracing axon pathways in experimental animals with specifically placed lesions. Improvements in staining methods used to selectively impregnate the disintegrating axons but to leave normal axons unstained were achieved by Nauta and Gyax (early workers with these procedures) and spawned a host of method variations known as the "Nauta" methods. Of these, the Fink-Heimer and de Olmos cupric-silver methods were able to unambiguously demonstrate disintegrating synaptic terminals, thereby allowing complete tracing of axon pathways. The late 1970s and 1980s witnessed innovative applications of these techniques. The silver methods once used to trace axon pathways became indicators of the extreme endpoint of neurotoxicity: disintegrative degeneration of neurons induced by neurotoxic chemicals that were administered systemically. The hallmark of neurotoxic substances is the selectivity with which each destroys specific populations or subpopulations of neurons. The high contrast and sensitivity of the silver degeneration stains greatly facilitate the screening process to detect these affected populations, especially when there is no basis for knowing where in the brain to look for damage. More recently, in addition to expanded use in screening for neurotoxic effects, the silver degeneration stains are being used to chart the neuron populations undergoing programmed cell death in the developing brain. Other newly developed silver methods have been refined to show nondisintegrative degeneration, such as the plaques and tangles of Alzheimer's disease.

Keywords. Amino cupric silver; apoptosis; brain; electron microscopy; fragmentation of proteins; MultiBrain Technology; neural tracing; neurohistology; neurotoxins; risk assessment

INTRODUCTION

The use of silver in staining protocols throughout the history of histology has been extensive. Parallel disciplines within the area of histology developed specialized silver staining methods that reflect those requirements unique to each. Increasingly in the last several decades, there has been a divergence in the information that is important to and shared by those laboratories with broad clinical demands vs those specialty laboratories that require new methods with which to explore the structure of the central nervous system. Perhaps, then, it is not surprising that the so-called "reduced silver methods" (which require external reducing agent vs tissue that "auto"-reduces silver) are not part of the standard histopathologic armamentarium.

The purpose of this review is to give a perspective on

the evolution of these silver stains and on their significance for contemporary use in assessing neurotoxicity. Some concepts of candidate mechanisms of these silver stains will be considered as well as suggestions for the design of studies for the detection of neurotoxicity.

HISTORICAL BACKGROUND

Axon Tracing

Excellent accounts of the historic trace of the neuro-histologic silver methods have been provided by Ebbesson (19), Heimer (36), Leonard (49, 50), de Olmos et al (16), and Beltramino et al (4). Drawing upon these accounts, the following historic vignette is provided.

Waller (82) observed in 1850 that transection of the hypoglossal and glossopharyngeal nerves produced a "kind of coagulation or curdling" of the nerve fibers. This "downstream" or anterograde degeneration came to be known as "Wallerian degeneration." The first person, however, to actually use the morphology of anterograde

Address correspondence to: Dr Robert C. Switzer III, NeuroScience Associates, 10915 Lake Ridge Drive, Knoxville, Tennessee 37922.

degeneration as a means of tracing axon pathways was Ludwig Turck, who preceded Waller in his report on spinal cord tracts by 1 year (49). According to Leonard (50), Cajal later found that these coagulated particles had a high affinity for impregnation by silver, but he did not further utilize this property.

In 1873, Camillo Golgi exposed brain tissue that had been hardened in potassium dichromate to silver nitrate and achieved results that revolutionized the study of the nervous system. A small percent of the neurons became impregnated with silver in their entirety such that the finest detail of the dendritic and axonal processes was revealed. This was the first of the so-called "reduced silver" methods. Cajal exploited this discovery, and through his work, he validated the neuron doctrine or theory of the structure of the nervous system. Ironically, Golgi was an advocate of the opposing line of thought—the reticular theory (68). The neuron doctrine stated that neurons with dendrites and axons as their parts are the basic units of structure of the nervous system. On the other hand, the reticular theory stated that the fine, branchlike structures (axons and dendrites) were continuous with one another and that neuron cell bodies provided a trophic/nourishing role (68).

The period from 1870 to 1910 was a golden era in that we gained an understanding of the structural elements of the brain. During this period, the Golgi and other stains were used to identify components of the nervous system and to ascertain the pathways of axons. Bielschowsky (5) introduced a silver method that, in contrast to the Golgi methods, essentially stained all types of cells and neural processes (Figure 1). The Bielschowsky stain became widely used, as it still is today, to identify abnormal features in the context of normally stained components.

Eventually these methods became limited because of the difficulty in finding the degenerating axonal elements among the normal axons that were also stained—today we call it poor "signal to noise" or just lack of contrast. It is the implicit goal of any histologic stain to provide contrast to different components of the tissue and, at the limits of this concept, to stain only those entities that are of interest while leaving other components unstained. Contemporary antibody staining exemplifies this process.

The solution to this lack of contrast came with the discovery of the way in which to utilize the fact that degenerating axons have a somewhat higher affinity for silver than do normal axons. This property was fully exploited in the 1940s by Glee's modification (31) of the Bielschowsky method (5) and then again by Nauta and Gyax in the early 1950s (59). The common feature in these successes was that the tissue was pretreated with various solutions prior to exposure to silver solutions. The result was a "suppression" of the silver impregnation in the normal axons and a rather intense impregnation of the degenerated axons; thereby, high contrast was achieved. These manipulations essentially "directed" the structures to be stained by the silver. Fink and Heimer (23) further refined the pretreatment strategy to obtain a technique that for the first time revealed degenerating synaptic boutons without the ambiguities that plagued other silver methods. Almost concurrently with the ef-

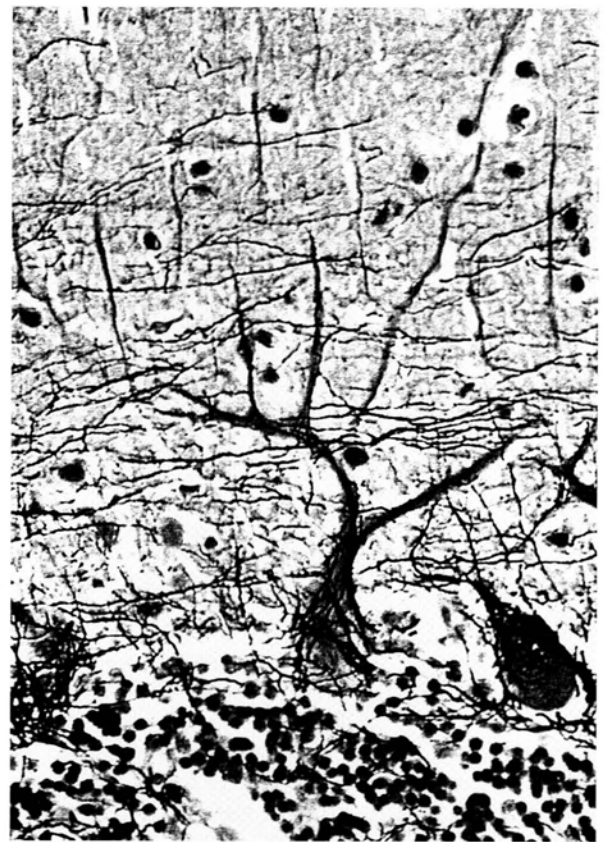

FIGURE 1.—Bielschowsky-stained section from human cerebellum. Cell bodies, dendrites, and axons are visible; 10 μ paraffin section.

forts of Fink and Heimer, de Olmos developed the cupric silver method (15), which, in its current form, provides the most sensitivity and the highest contrast (high signal-to-noise) images.

Later protocols developed by Gallyas took the variety of pretreatments to new levels of directed staining (26–29). It is interesting to observe that the principles underlying the steps used to achieve "directed staining" are analogous to those associated with the use of mordants (definition: to treat with a chemical that confers the ability to combine with dyes) in other disciplines of histology.

Contemporary Use for Neurotoxicity Detection

Beginning in the late 1970s, other methods for tracing axon pathways became available (tritiated amino acids, horseradish peroxidase, and fluorescent markers), and the frequency of use of silver degeneration methods rapidly declined. At about the same time, however, a new use of the silver degeneration stains began to evolve: detection of damage to the nervous system caused by chemical agents. The level of damage registered by these silver stains is that characterized by destruction of neural elements. Loss of neurons is the ultimate endpoint of the various measures of neurotoxicity, because neurons do not regenerate (75). Table 1 lists the first studies to systematically administer a known or suspected neurotoxin and to use a silver degeneration stain to detect the areas of damage.

TABLE 1.—Chronology of use of silver degeneration stains to detect neurotoxic damage following systemic exposure to different agents.

Substance/agent	Target/susceptible areas	Authors	Year	Reference
Tetanus toxin	somatosensory fibers	Illis and Mitchell	1970	42
6-Hydroxydopamine (6-OHDA)	substantia nigra	Hedreen and Chalmers	1972	35
3-Acetyl pyridine	inferior olive, n. ambiguous	Desclin and Escubi	1974	18
High-pressure oxygen	auditory nuclei	Switzer	1980	69
Capsaicin	somatosensory fibers	Jancso and Kiraly	1980	43
Soman (nerve gas organophosphate)	hippocampus, pyriform cortex	Petras	1981	66
Methamphetamine	striatum, cortex	Ricaurte et al	1982	67
Alcohol	entorhinal cortex, hippocampus	Switzer et al	1982	72
Kainate	hippocampus, pyriform cortex	Jarrard	1989	45
MPTP (1-methyl-4-phenyl-1,2,3,6-tetrahydropyridine)	substantia nigra, thalamus, n. sagulum	Switzer and Campbell	1987	70
Trimethyltin	hippocampus, cortex	Balaban et al	1988	1
Tri-ortho-cresyl-phosphate (TOCP; Type I OPIDN)	spinal cord, brain stem, cerebellum	Tanaka and Bursian	1989	80
Tri-phenyl phosphite (Type II OPIDN)	spinal cord, brain stem, cerebellum, thalamus, cortex	Tanaka et al	1990	81
MDMA (methylene-dioxymethamphetamine)	cortex	Jensen et al	1990	46
Glutamate	cochlea	Janssen et al	1991	44
Cocaine	fasciculus retroflexus	Ellison	1992	20
MK-801 (dizocilpine maleate)	cingulate, olfactory cortex, hippocampus	Corso et al	1992	10
Phencyclidine (PCP)	cingulate, entorhinal cortex, hippocampus	Ellison and Switzer	1993	21
Domoic acid	hippocampus	Peng et al	1994	62
High energy (MeV) electrons and protons	β astrocytes	Switzer et al	1994	77
3-Nitropropionic acid	striatum, cortex, hippocampus	Miller and Zaborszky	1997	56

Silver Staining and How a Neuron Dies. “Do the silver degeneration stains show neurons that died by apoptosis?” is a frequently posed question. As is becoming increasingly evident, there are numerous routes, pathways, or mechanisms that can lead to the death of the cell (52, 55). After a neuron is “dead,” it disintegrates, and, as will be discussed later, it is the debris from this disintegration that is registered by the silver degeneration stains. This multi-option process is depicted in Figure 2 and is compatible with insights recently expressed by Levin et al (52). One or more of the hypothetical sequences shown could be apoptotic or oncotic in nature. The term necrosis is reserved for a “final common pathway” of dissolution (disintegration) leading to the products that are the suggested moieties “stained” by the silver. At this point in the sequence, the silver degeneration stain indicates that cell death occurred, but it cannot provide the means to determine if the events that initiated the sequence leading to cell death were oncotic or apoptotic.

Evidence is being accumulated in our laboratory that indicates that the appearance of neuronal debris is a function of how the cell died. For example, the debris of neurons in cingulate cortex that were “killed” by an acute exposure to soman is not in evidence 4 weeks after exposure. However, a 5-day subchronic exposure to soman yields cell body-sized packets of silver-impregnated debris in the same location (73). Evidently, differences in the agonal process can yield different presentations of neuronal cell debris. This is consistent with and complements the findings that the morphology of dying neurons is a function of the form of insult (51, cited in 52).

Currently, the disruption of the chronology of apoptosis (or programmed cell death) in the developing brain is an issue of concern. The silver degeneration methods have recently been shown (57, 79, 83) to be a useful tool in assessing the timetable of “cell death-days” for neu-

ronal populations as a complement to the well-documented patterns and chronology of “cell birthdays.” This tabulation may identify other critical periods during which development may be perturbed.

Interpretation of Silver Degeneration Staining. During the time when silver degeneration methods were used extensively for axon tract tracing (1950–1970), a number of articles gave in-depth discussions, with extensive illustrations of silver-impregnated features that were associated with disintegrative degeneration (4, 16, 19, 36, 50). Brain sections stained with the Fink-Heimer and de Olmos cupric silver methods had excellent signal-to-noise characteristics, such that it could be generally said that “if it was impregnated by silver, it is degenerated.” The dichotomy of the features stained offered enormous value for detecting degeneration—hence, the value for indicating neurotoxicity.

With the development of more contemporary silver protocols, the sensitivity of the staining has increased. Features not visible with earlier methods can now be seen soon after the insult occurs (14, 30). While this may be advantageous from some perspectives, it can potentially lessen the dichotomous “all or nothing” characteristic and requires that the investigator use appropriate survival times to avoid ambiguity. For example, the new methods can silver-impregnate neurons that have been traumatized only a matter of minutes to hours prior to sacrifice (14, 30). This is certainly of value in terms of detecting the neuronal populations perturbed by a particular form of insult, but with very short survival times, a conclusion cannot be reached as to whether the neurons will subsequently die. A similar situation exists for neurons that express heat-shock protein, HSP-70, or c-fos, in that both reveal perturbed neurons, but which, if any, would die cannot be determined.

The valuable dichotomy of silver-stained features is preserved if the investigator judiciously selects the times

Schematic of cellular events that follow various perturbations

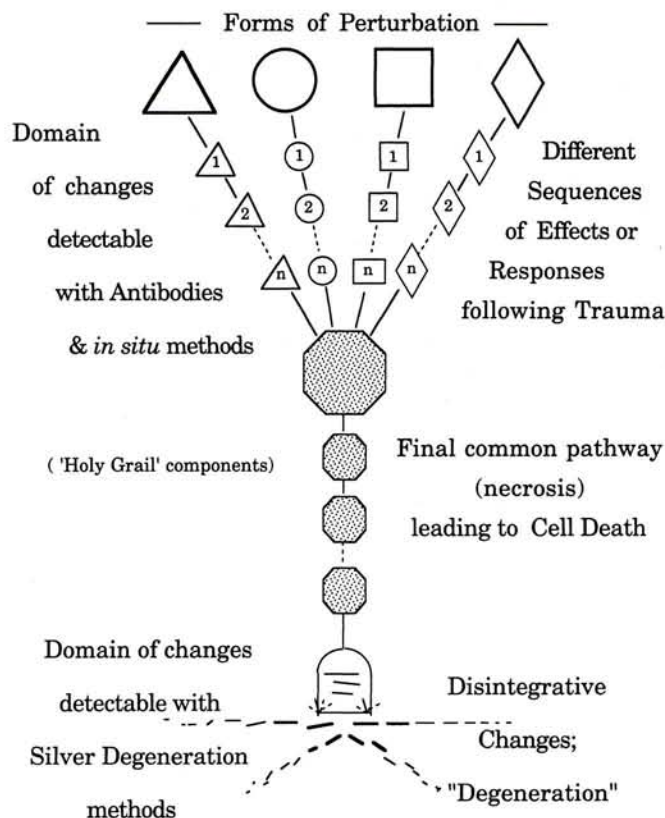


FIGURE 2.—Schematic of potentially neurotoxic biochemical changes that follow different forms of perturbation: stages of applicability of antibody markers and silver degeneration stains. The spectrum of neurotoxic effects encompasses a broad range of changes in a cell that can culminate in its death. Depending on the form of insult, a different sequence of effects may ensue, all of which may be reversible. In the extreme, any given perturbation or trauma (the geometric forms at the top) can result in the death of the cell, even though it may occur by different sequences, as indicated by the strings of small, numbered geometric forms. All of these, however, converge on the stippled polygon to traverse a final common path of changes (small stippled polygons) that results in cell death. Antibody probes have been developed against different proteins (depicted by triangle-2 or diamond-1) that are constituents of the sequence of biochemical changes that follow a particular form of trauma. Unless an antibody is directed against a component along the "final common path" to cell death, the presence of immunoreactivity of proteins in the earlier sequences does not necessarily mean cell death. Since it is uncertain whether or not even a polyspecific antibody could be raised against the amorphous disintegrative debris of a degenerated cell, the silver degeneration stains currently remain the best probe to mark this endpoint of neurotoxicity.

of sacrifice after insult. By allowing a set of animals subject to the same trauma to survive 2–4 days, the morphology of any silver-stained neurons will indicate the death of that neuronal element.

With de Olmos's new amino cupric silver method (14), the silver impregnation of degenerated structures is more intense, and the background is clear. The amino cupric silver method also has the advantage of being able to stain brain tissue that has not been optimally fixed, such as the case in human autopsies. Other unidentifiable technical aspects that perturbed earlier silver degeneration

methods seem less influential with the amino cupric silver method.

Appearance of Silver Staining

With the aid of relatively few silver-stained slides, a pathologist can become acquainted with the characteristics of the silver degeneration stain in just a few hours. Some of the photographs shown in Figure 3 illustrate the kind of material such a study set would comprise.

With the amino cupric silver stain, degenerative features undergoing various degrees of disintegration are selectively impregnated and are seen as black or black-brown profiles against a clear background. With de Olmos's original version, as well as with most of the so-called "Nauta variants," the background is dark to light amber (Figure 3A). The time of appearance of disintegrated neural components is dependent on the duration of survival following the neurotoxic insult. Degenerating dendrites and axon terminals (Figure 3A, B, F) appear early (after a few hours), but their debris is no longer evident after about 3–7 days. Degenerating cell bodies (Figure 3A, B, D) can be seen shortly after the appearance of degenerating terminals, but cell body debris is also cleared by 7–10 days after the insult. Degenerating axons (Figure 3C, D, E) and associated debris are the last to be observed and may persist for remarkably long periods of time (33). These elements can be seen beginning at about 2–3 days after the insult, and this debris can still be stained 9 months later in rats. In primates, especially humans, the axonal debris can be stained after more than 1–2 years (33). Therefore, if debris associated with the death of neuron cell bodies is no longer present, the axonal debris of these cells may still be stainable and will provide conspicuous evidence of the neurotoxic event.

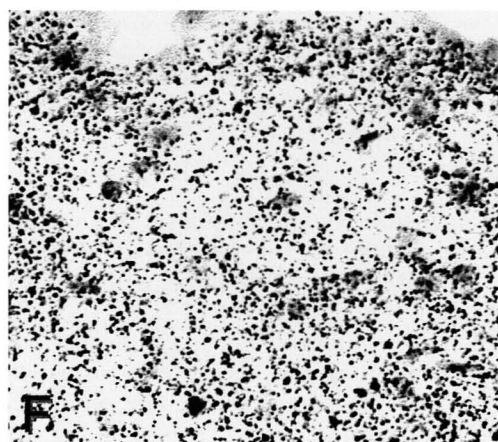
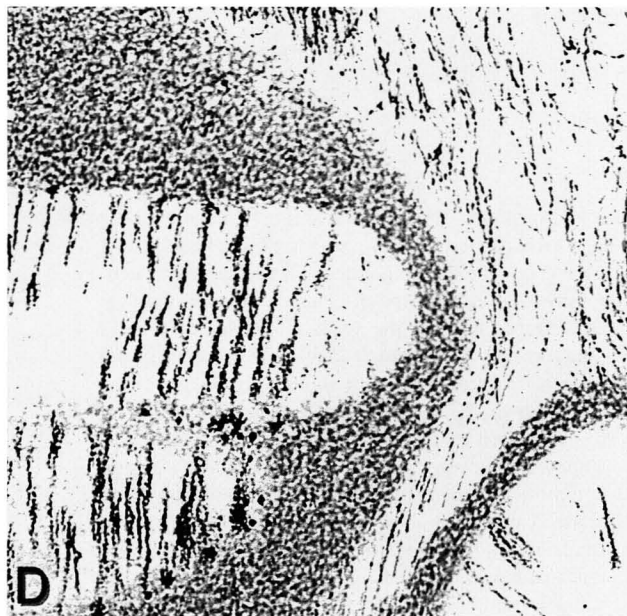
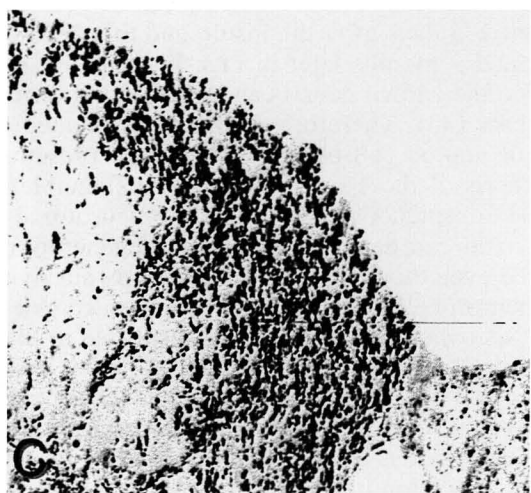
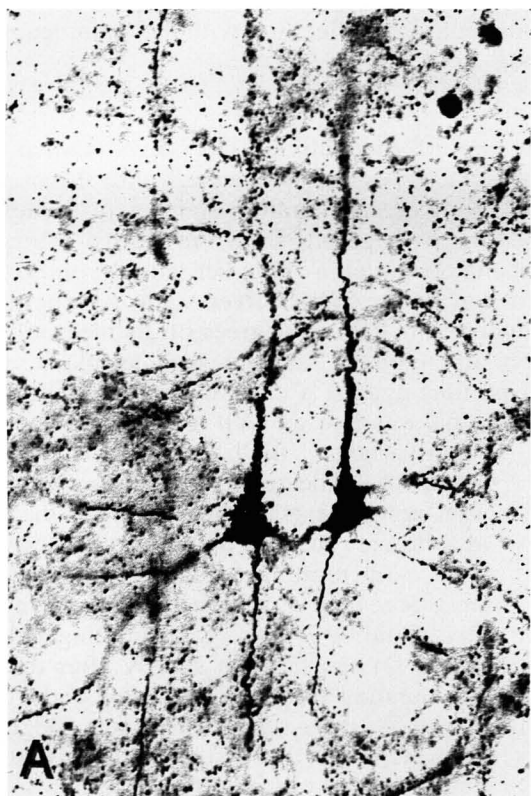
An axon can degenerate and the degeneration can be detected even though the parent cell body survives. Often such neuron cell bodies display changes known as chromatolysis, wherein the nucleus is displaced to the periphery, the cell is swollen, and the Nissl bodies are reduced and located at the cell margin (22). Chromatolysis is more extensive and extreme in the immature nervous system. The incident causing the distal axon to degenerate can be transection or trauma somewhere along the length of the axon (causing Wallerian degeneration) or at the terminus of the axon, which causes a dying back phenomenon (retrograde degeneration) (34).

Conceptually, in long-term neurodegenerative diseases, there could be routes to cell death that generate disintegration products at such a slow rate that at any given time, not enough debris is present to yield much binding of silver (thus resulting in a weak signal). For example, in our staining of brains from Parkinson's disease victims, degenerating axons from substantia nigra to the striatum are not seen.

MECHANISM OF STAINING

Historic Perspective

The question of mechanism of staining is usually one of the first questions asked by those individuals first presented with the potential of using these silver stains to assess neurotoxicity. Similar questions were asked during



the 1960s and 1970s as new silver methods arose. In fact, it seems that as any given silver method became more directed, questions regarding validity and explanations of mechanisms of staining were expected. It is not within the scope of this review, nor it is within the expertise of the author, to provide a definitive explanation for why silver can reveal any given feature, since at best, the mechanism of staining is poorly understood, in spite of considerable efforts (63–65).

In Table 2, several silver methods are presented, along with their generic steps. Progressing from left to right, it can be seen that as the methods acquire more or different steps (especially pretreatments), they become more or differently "directed" in terms of the features that are stained. The features stained are dependent on the composition of the solutions at each of the steps: pretreatment, silver incubation, a second silver (if present), the reducer (developer), bleaching, and stabilization.

In order to illustrate the complexity of factors involved in any given silver stain, consider that the same method used to reveal disintegrative degeneration (the cupric silver method) was successfully applied to reveal complex mixtures of proteins that were separated by 2-dimensional gel electrophoresis (Figure 4A) (78). The proteins in these gels are not "disintegrating"; that is, they are not fragmented, but they are unfolded, and side groups are exposed. Furthermore, in brain sections from victims of Alzheimer's disease, the silver degeneration stains do not stain the plaques and tangles that are revealed with other silver stains (Figure 4B).

These few examples illustrating the diversity of silver also provide some insight regarding the reputation of the silver methods as being "capricious." It is ironic that the virtue of versatility of silver can also be a curse. We have seen that numerous factors can direct silver to stain features of interest. However, if unintended factors (contaminants) are present, the silver staining can be misdirected and may yield undesirable results or outright failure. As is true for procedures in biochemistry and biotechnology in general, so it is for silver methods that purity of reagents and exacting execution of the protocol are necessary for consistent and reliable results.

It can be inferred from the comparison of methods in Table 2 that although some common principles underlie the mechanisms of staining, there is likely to be a different set of mechanisms for each stain. Silver is only 1 factor (albeit, a crucial one) in the ensemble of directive factors for each method. In order to gain a perspective on just some of the possibilities for mechanism of staining, other applications of silver as a "stain" are shown in Table 3.

Working Hypothesis

Although an explicit mechanism cannot be provided for the silver degeneration stain, a working hypothesis or conceptual vehicle can be offered (Figure 5); this hypothesis was inspired in part by experiments using puromycin as a "lesioning" agent (74). Single and short chains of amino acids are known to form complexes with silver ions as well as with other metals, such as copper (8, 25). Different amino acids have different affinities for the binding of silver (6) that can even provide a color dimension. It is commonly thought that those amino acids with single sulfide groups have the largest affinity, but through the formation of complexes with amino acid carboxyl and amine terminal groups, as well as side groups, the opportunities for silver ions to form complexes are numerous.

In the environment of an intact protein that is more or less globular in shape, many of these groups are not accessible to silver ions. In a cell undergoing degeneration, proteolytic mechanisms begin to dismantle proteins, and in the process, they expose more sites for silver to form complexes. This scenario is depicted at the bottom of Figure 5.

Each site at which the complexes form can be thought of as a nucleation point around which other silver ions aggregate, as was suggested by Liesegang (53) when he put forth this hypothesis in 1911. This is comparable to the events in the photographic process. From the physicochemistry of photography we learn that photons striking a silver-laden photographic emulsion create a nucleation point around which other silver ions gather during "development" (reduction), and these nucleation points

←

FIGURE 3.—Examples of silver degeneration staining. A) The cell body, dendrites, and portions of their axons are impregnated in this pair of pyramidal cells in rat neocortex. Dendritic fragments are seen as either continuous lines or linear arrays of dots from other cell bodies out of the plane of section. The lesion was induced by puromycin 2 days prior to sacrifice (74); Stain: de Olmos cupric silver method; 40- μ freeze-cut sections. B) Pyramidal cells of the hippocampal CA1 region in a rat exposed to the organophosphate soman. Clusters of pyramidal cell bodies with large sprays of dendrites are visible in a degenerated state. Unaffected pyramidal cells are seen as grayish profiles in line with the silver-impregnated cell bodies; Stain: amino cupric silver method of de Olmos, with neutral red counterstain; 40- μ freeze-cut sections. C) Cuneate tract in the dorsal spinal cord from a rat. Silver-impregnated degenerated axons are shown in transverse section. Lesion was of unknown origin; Stain: amino cupric silver method of de Olmos; 40- μ freeze-cut sections. D) Rat cerebellum in coronal plane displaying degenerated cell bodies and axons following acrylamide exposure. Purkinje cell bodies and their dendrites are visible in the lower left quadrant of the image. Linear arrays of degenerated axons are numerous in the right half of the image. If the plane of section had been in the sagittal plane, the fan-shaped geometry of the Purkinje cell dendrites would have been visible; Stain: amino cupric silver method of de Olmos, with neutral red counterstain. E) Rat trapezoid body in coronal plane displaying degenerated axons following acrylamide exposure. Both large and small caliber axons are degenerated. In normal rats and other species, a few of the large axons can routinely be found as degenerated. This can serve as a partial positive control for the silver staining; Stain: amino cupric silver method of de Olmos. F) Degenerated synaptic terminals (boutons) in layer I of rat neocortex after MK-801 intoxication. The characteristic punctate appearance of silver-impregnated degenerated synaptic terminals is displayed in this image of the layer I in the retrosplenial-agranular/visual cortex. Sacrifice of the rat was 2 days after exposure to MK-801. After 3–4 days, the debris associated with these terminals would no longer be present and therefore would not be impregnated by silver.

TABLE 2.—Comparison of silver staining methods by comparison of steps and staining: results for degeneration and neuritic plaques and tangles of Alzheimer's disease.

Type of step	Staining methods (reference number)			
	Bielschowsky (5)	Bodian (41)	Campbell– Switzer (9, 71)	Cupric Silver– deOlmos (17)
Pretreatment			NH ₄ OH dilute	
Primary incubation	AgNO ₃	protargol (silver-protein) metallic copper	AgNO ₃ pyridine K ₂ CO ₃	AgNO ₃ CuNO ₃ pyridine ethanol
Intermediate			citric acid acetic acid	
Secondary incubation	AgNO ₃ NH ₄ OH			AgNO ₃ NaOH NH ₄ OH
Reduction/development	formaldehyde AgNO ₃ NH ₄ OH citric acid nitric acid	hydroquinone + Na sulfite	formaldehyde AgNO ₃ tungstosilicic acid Na ₂ CO ₃ NH ₄ CO ₃	formaldehyde ethanol citric acid
Toning		gold chloride		
Postreduction (color differentiation)	oxalic acid	Na thiosulfate	K ferrocyanide Na borate	
Features stained				
Neuronal degeneration	no	no	no	yes
Neuritic plaques and neurofibrillary tangles	yes	yes	yes	no
Background fibers	yes	yes	no	no

subsequently become macroscopically visible aggregates (47). This is a process of considerable amplification, and it gives silver enormous benefits. Similar hypotheses have been made regarding the mechanism of the Timms silver sulfide staining for zinc by Danscher et al (12) and by Gallyas (26) to explain the mechanism underlying the family of physical developers that he formulated.

Electron Microscopy Evidence of Silver Deposition Sites

Is the silver really impregnating degenerating elements? As the ability of any of the silver stains became more selective for the features impregnated, issues of validity arose. This was especially true for the silver degeneration methods that claimed to stain degenerating synaptic terminals, such as the Fink-Heimer method. In response to this challenge, Heimer and Peters (38) demonstrated by electron microscopy that silver was preferentially deposited in synapses that were degenerating, as determined by their ultrastructural characteristics. Curiously, one of these characteristics is higher osmiophilia. This raises the following question: Are the underlying causes for osmiophilia the same as those that cause the degenerating structures to be argyrophilic? Other reports (33, 36, 83) corroborate the findings of Heimer and Peters.

SUGGESTIONS FOR OPTIMIZING EXPERIMENTAL DESIGN

Among the strategies for assessing neurotoxicity, the next most important experimental variable in terms of the

parameters of exposure is survival time: the interval of time between treatment exposure and the sacrifice of the animal (75). Some induced neurotoxic changes can occur in a matter of minutes, as is the case with the c-fos and heat-shock proteins, and then disappear almost as quickly (or in a matter of hours). Other changes have time frames on the order of days and weeks. These are more experimentally desirable in that there is a broader "window" of time during which they can be observed, which reduces the risk of false-negative results. The approaches discussed here have broad windows of opportunity for observation. This helps ensure the likelihood that degenerating neurons will be stained by silver and that the positive findings will be detected by the pathologist.

Cupric Silver

The silver degeneration methods are generally applied to sections from animals that have been sacrificed 2–3 days after acute treatment. By this time, disintegration of neural elements has already begun. In some instances, the silver impregnation can be observed in less than 24 hours. In order to ensure that the silver-impregnated features are actually in an irreversible disintegrative state and not merely a perturbed state, it is important to select a survival time (after exposure) that will allow enough time for the disintegrative process to take place.

Optimal survival times for observing degenerated states for different neural elements are as follows: Synaptic terminals, 1–3 days; cell bodies and dendrites, 1–4 days; and axons, 3–7 days. However, as previously de-

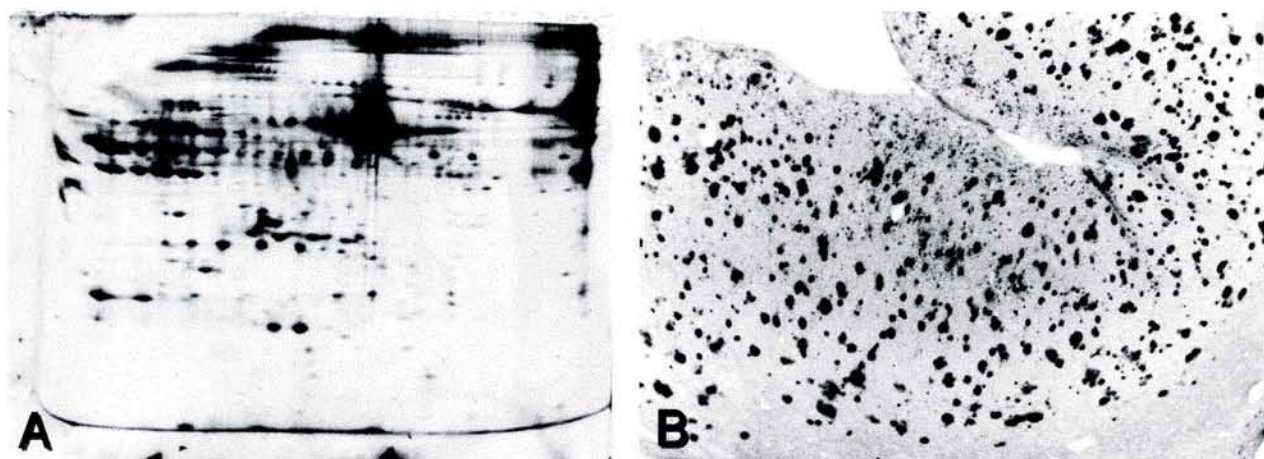


FIGURE 4.—Example of silver staining applied to other methodologies. A) A complex mixture of proteins separated by 2-dimensional gel electrophoresis and rendered visible by the cupric silver staining method of de Olmos is displayed. The process of mobilizing the proteins and separating them by electrophoresis leaves the proteins intact but unfolded, thereby exposing numerous side groups, with which the silver ions hypothetically form complexes. B) In this view of human temporal lobe cortex, the neuritic plaques and tangles (not shown) of Alzheimer's disease (AD) are rendered visible with a silver staining protocol employing a silver-pyridine-carbonate incubation and reduction using a Gallyas physical developer (9, 71). These features are not stained by the cupric silver methods, and the AD stain does not reveal features of disintegrative degeneration.

scribed, the debris of axons in humans can still be impregnated months to years after destruction of the axons (33).

For a longer subchronic study, survival times of 2 and 7 days after the final dose and of 2, 4, and 8 weeks are recommended. These times cover the time domains of acute effects (2 and 7 days) and possible delayed effects (2, 4, and 8 weeks).

Persistence of the axonal debris can still allow damage to be detected if conditions of the experimental design (for example, the need to do behavioral observations or adherence to a regulatory agency's guidelines) do not permit the above array of survival times. Depending on the degree of damage, the residual debris of cell bodies may still be present after long survival times (such as 4 weeks). If a large lesion was induced, abundant axon debris can persist for at least 9 months in rats.

Control Over Variations in Staining

In spite of diligence and exacting execution of any protocol, differences in staining can occur on different sessions of staining unless they are performed by a not-yet-existent robotic system. Such differences can be especially problematic in studies in which different dosage groups and controls are to be compared. In order to ensure uniformity of staining across a number of rodent

brains, the brains can be embedded together in a suitable matrix [eg, egg yolk, egg yolk-albumin, albumin-gelatin (19), or gelatin alone (7)]. The matrix holds the tissue in place throughout sectioning and staining so that all individual brain sections in the macro section experience the same staining conditions. For example, a commercial neurohistologic service offered by Neuroscience Associates uses MultiBrain Technology, wherein 16 rats or up to 25 mice are embedded together in a gelatin matrix (as shown in Figure 6A). This technology yields large-format, macro sections, with individual brain sections present in a 4×4 array on 2×3 -inch slides (Figure 6, inset).

RATIONALE FOR SILVER DEGENERATION STAINING

Brain function depends on the integrity of individual neurons and the circuits they form. Loss of neurons is, then, the ultimate endpoint of the various measures of neurotoxicity, because neurons do not regenerate (76). Whether or not behavioral symptoms are present as a result of the loss of neurons depends, of course, on which system is involved and on the extent of cell loss. For certain systems, the loss of some fraction of their cells would be subsymptomatic, which really means that the loss of cells falls within the system's capacity to functionally compensate. It is most important to realize, how-

TABLE 3.—Uses of silver in non-nervous system applications.

Thin-layer chromatography (reference 13)	Biochemistry (reference number)	Histology (reference number)
Hydrazides, hydrazine		reticulum 958)
<i>o</i> -, <i>m</i> -, <i>p</i> -Aminophenols	2-dimensional gel electrophoresis (78)	melanin (2)
Methylglyoxal	DNA/RNA (3)	fungi (40)
Enols and oxidizable phenols		chromosome bands (39)
Thiol barbiturates		nucleolar organizing regions (32, 54, 61)
Alpha keto groups in corticosteroids		heavy metals (Timm's method) (11)
Reducing sugars, inositol groups		
Reducing and nonreducing centers in biochemical compounds		

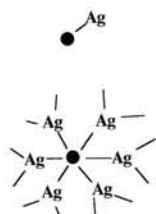
Suggested Sequence for Basis of Silver Degeneration Stains

---AA Ag AA---

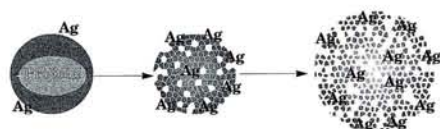
Silver forms complexes with individual Amino Acids

---AA AA AA Ag AA Ag AA AA Ag AA AA Ag AA---

Silver complexes with individual Amino Acids or sequences of Amino Acids (peptides) to form short to long chain lengths



Silver ions form nucleation points around which other Silver ions aggregate



Disintegration of proteins provides more nucleation points for Silver ions

FIGURE 5.—Hypothetical basis for silver binding to disintegration products of proteins in degenerating neurons. This figure depicts 1) silver forming complexes with individual amino acids; 2) complexes of silver and short chains of amino acids (8, 25); 3) silver as a nucleation point for further silver ion aggregation (12, 26, 53); and 4) comparison of silver binding opportunities in intact and disintegrated proteins. Progressive fragmentation of proteins (proteolysis) in disintegrating neurons leads to increased sites for silver to form complexes (74).

ever, that because of this cell loss, the capacity for compensation for future insults is diminished. Neurologic symptoms that occur later in life may be the deferred manifestation of an earlier exposure to a neurotoxic agent or condition.

It is important, then, to identify any cell loss or destruction of neural components, regardless of the absence of behavioral signs. (Do we have an armamentarium of behavioral tests that is sensitive to all cerebral functions? I think not.) Identification of the system with damage will at least give direction to the behavioral scientist in terms of predicting the functions that might be perturbed by the loss or damage of a particular set of cells. The behavioral scientist or clinical neurologist can then select an appropriate behavioral test.

Exposure to a chemical or to external influences (such as ionizing or non-ionizing radiation or contaminated atmospheres) can certainly be expected to have the potential to induce changes in the brain that do not involve the death of neurons. Some of these changes may be reversible whereas others may not. The changes can be structural (eg, pruning the branches of dendritic trees) or biochemical, affecting cell metabolism and neurotransmitter pathways, etc. Detecting changes that do not cause the death of neurons poses the greatest challenge to the neurotoxicologist.

There are many specific probes that have been developed to detect the changes that take place in neurons following a given level of perturbation. Some of these occur in succession to one another, thereby forming a sequence. The length or duration of this sequence may be dependent on the nature and degree of perturbation or insult to the system. For example, subtle perturbations may induce the expression of intermediate early genes or heat-shock proteins. If the insult causes more permanent damage, transcription for molecular entities associated with repair will occur. In spite of these cellular responses,

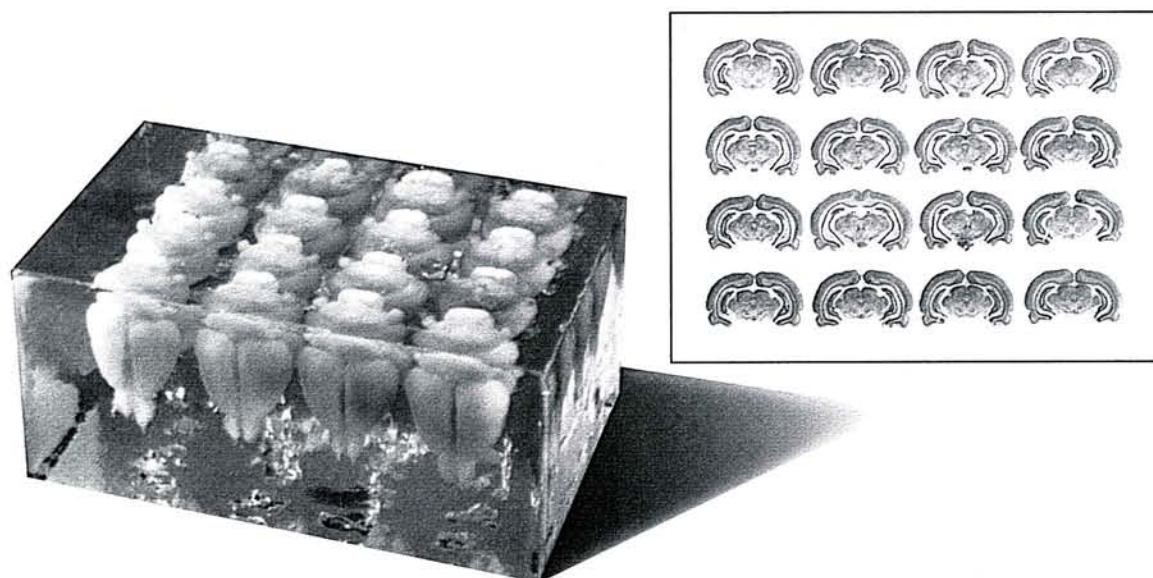


FIGURE 6.—An array of 16 rat brains is shown embedded in a matrix, composed primarily of gelatin using MultiBrain Technology (NeuroScience Associates, Knoxville, TN). The inset displays a macro or multibrain section that was freeze-cut from the block, mounted, and stained with thionine for Nissl substance. Uniform staining across the individual brains is a prime advantage of these large-format sections.

the form and/or degree of insult may overwhelm the cell beyond recovery, thereby resulting in the cell's death and disintegration. As described earlier, Figure 2 depicts hypothetical levels, or a "flow chart," of such sequences.

The particular form of an insult that ultimately causes the cell to die can be expected to determine the premortem sequence of changes that takes place. Death by mitochondrial poisoning, blockage of protein synthesis [eg, puromycin (74)], blockage of transcription from DNA (eg, actinomycin-D), or ion channel blockers (to suggest but a few) can result in different sequences of chemical changes that can be markers of a particular route to death. Clearly, the "Holy Grail" of markers of irreversible neuronal injury is that which is present only when the cell will subsequently die.

Changes in cells other than neurons constitute indirect markers of neuronal injury and death. For example, proliferation of glia (gliosis) at the site of damage and increased synthesis of the astrocyte-specific protein glial fibrillary acid protein (GFAP) have been commonly used as evidence of neurotoxic effects (60). Often, the occurrence of either of these is coincident with the destruction of neural elements. However, there are also examples of increased GFAP expression that is not attended by degeneration of neural elements (48).

Classical histopathologic methods stain various components of an injured or dying neuron differently than they do those of a normal neuron. Using the hematoxylin and eosin (H&E) staining method (the gold standard of histopathology), the term "red and dead" is an apt expression applied to the appearance of the cytoplasm in a neuron that has just died. If such cells are not coalesced and part of a massive lesion but instead comprise a dispersed population among normal-appearing cells, detection is difficult, since it requires microscopic examination at relatively high magnifications (24). These classical methods are also incapable of revealing little, if anything, about the demise of synaptic terminals, dendrites, and axons (especially unmyelinated axons). Traditionally, the H&E stain is the only stain applied to sections in a toxicity assessment. As shown below, exclusive use of classical histopathologic techniques is fraught with the potential for false-negative results.

Shown in Figure 7A through D are examples of classical H&E and cell body stains compared with silver degeneration staining. Figure 7B shows a section stained with thionine (the staining of this dye is comparable to that of cresyl violet) to reveal the nucleic acids of Nissl substance and DNA in cell bodies. Figure 7A displays an adjacent section that was stained with the amino cupric silver method, which reveals disintegrative degeneration of neural elements resulting from treatment with the organophosphate nerve gas soman.

The thionine-stained section appears normal at this relatively low magnification. No loss of cell bodies is evident. In the amino cupric silver-stained section, however, the black profiles and attendant dendritic debris indicate that a subpopulation of neuron cell bodies has degenerated. Examination of the section stained for cell bodies alone would most likely have yielded a false-negative result unless this sample was examined at high magnifi-

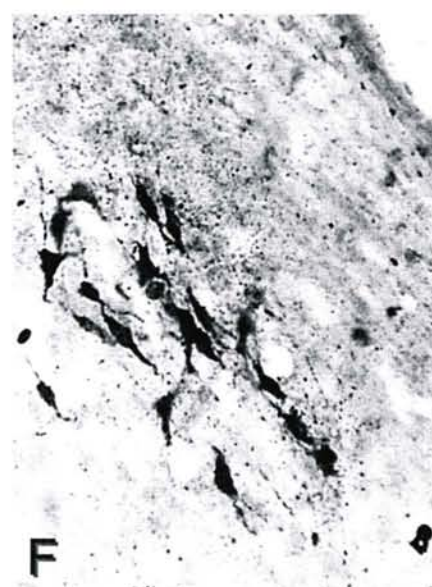
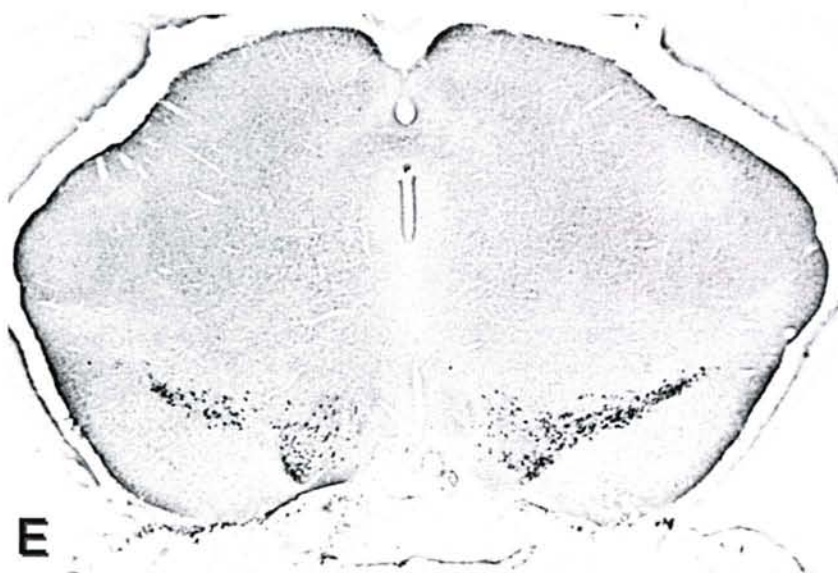
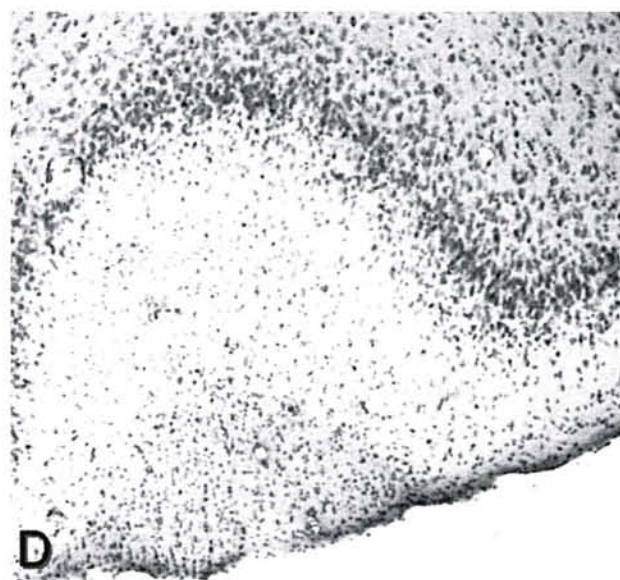
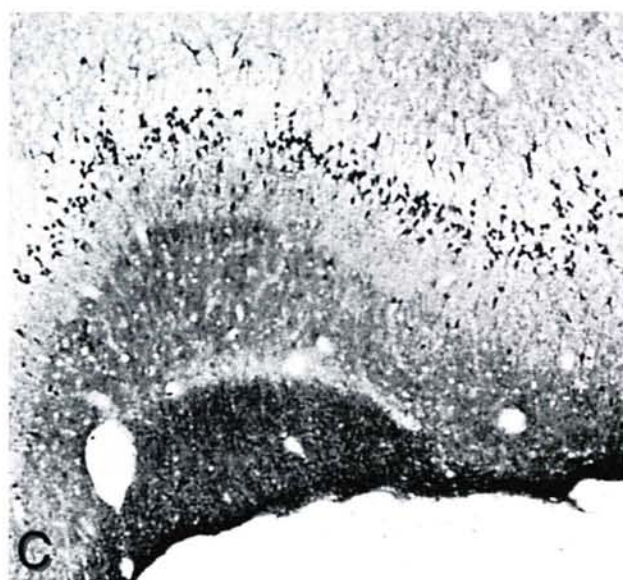

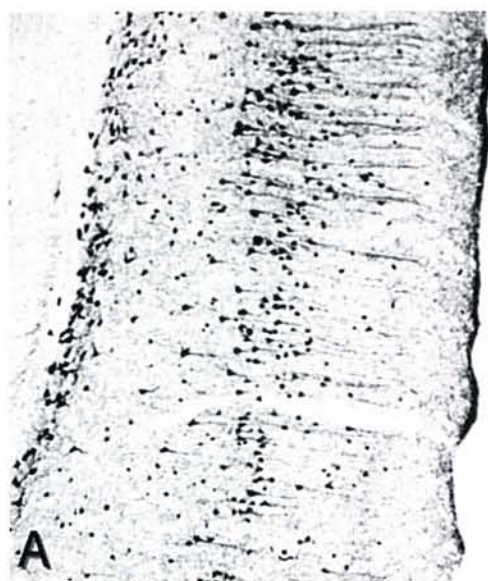
cations in order to detect pyknotic or karyoclastic nuclei. The high contrast offered by the silver degeneration stains greatly accelerates the pathologic review process, and this process can be completed with a greater likelihood that nothing has been missed.

Another display of degeneration can be induced in the olfactory cortex by transection of the olfactory bulb (37). Because of a transneuronal effect, the layer I cells of the olfactory cortex undergo a rather fulminant degeneration. In spite of the high density of cells visible with the cupric silver stain (Figure 7C), the same appreciation of these events is not obvious in an adjacent section stained with H&E. At higher magnifications, however, neurons showing pyknotic or karyoclastic nuclear profiles were more clearly evident in the same location as the silver-impregnated cells. With increasing time after the transection of the olfactory bulb, these nuclear fragments in each cell became more numerous and smaller, and by the fifth day, they could no longer be seen. This pattern was paralleled by a diminishing intensity of the eosinophilia, which was virtually extinguished by the fourth or fifth day. Debris of these cells continued to be impregnated by silver through the fifth day, thereby providing a broader window of time for detection of the degeneration.

Both of these examples illustrate that in Nissl- or H&E-stained sections, unless the observer knows where to look, degenerative events may be missed. Another excellent example of the advantage of the high contrast provided by the silver degeneration stain is found in the degeneration induced by 1-methyl-4-phenyl-1,2,3,6-tetrahydropyridine (MPTP), which induces a Parkinson's disease-like lesion by destroying substantia nigra neurons (Figure 7E, F). Since MPTP was believed to only affect dopaminergic neurons, it was quite unexpected to find the neurons of the nucleus sagulum, as well as some thalamic cell groups (70), in a state of disintegrative degeneration, as is shown in Figure 7F.

Paraffin vs Freeze-Cut Sections

These above comparisons have been made with freeze-cut 40- μ -thick sections, and the point has been made that standard H&E paraffin sections would have shown features that the H&E-stained freeze-cut section did not. Paraffin sections of nervous system tissue are typically 5–10 μ thick, and freeze-cut sections are typically 30–40 μ thick. The same tinctorial changes in H&E staining can be seen in both types of sections, but the contrast of these changes and the cytological detail visible in the thinner paraffin sections is superior to that associated with freeze-cut sections in terms of making cell-by-cell examinations. On the other hand, there is a spatial dilution with the thinner paraffin sections, so that a lesser volume of tissue is being examined. In freeze-cut sections, more cells with potential changes are available within a given field of view, and subtle changes in the cytoarchitectonics can more readily be appreciated. The ability to do silver degeneration stains on freeze-cut sections provides a high-contrast image of degeneration that is visible at low magnifications—this provides an enormous advantage in terms of analysis.



CONCLUSION

Nearly all known neurotoxins have been discovered through human incident that was attributable, perhaps, to the lack of sensitive and efficient means for conducting neurotoxicity screening. Now, however, the use of the silver degeneration stains early in the toxicologic screening process provides researchers with the potential to detect neurotoxic effects that might otherwise only be discovered later (by effects on humans).

The silver degeneration stains have unmatched properties for detecting early as well as chronically occurring neural degeneration, and they should be considered an essential part of the complete neurotoxicologic assessment battery. A great deal of credit is owed to all the scientists who, by developing and using silver stains during the last century, have brought this staining technology to its current state. We are now poised to witness yet another major contribution to be made through the application of the silver degeneration methods to screening for potential neurotoxins in routine safety assessments conducted for chemicals and new drug entities.

ACKNOWLEDGMENTS

The author thanks Dana Wheat and Julie Switzer for their assistance and editorship in the preparation of this manuscript. Drs Brad Bolon, Karen Regan, and Steve Sparenborg contributed valuable, early discussions on content, and Dr Andrew Fix critically reviewed the final draft.

REFERENCES

- Balaban CD, O'Callaghan JP, Billingsley ML (1988). Trimethyltin-induced neuronal damage in the rat brain: Comparative studies using silver degeneration stains, immunocytochemistry and immunoassay for neuronotypic and gliotypic proteins. *Neuroscience* 26: 337-361.
- Bancroft JD (1975). Masson Fontana method for melanins and argentaffin cells. In: *Histochemical Techniques*, 2nd ed. Butterworths, Boston, p 191.
- Bassam BJ, Caetano-Anolles G, Gresshoff PM (1991). Fast and sensitive silver staining of DNA in polyacrylamide gels. *Anal Biochem* 198: 217.
- Beltramino CA, de Olmos JS, Gallyas F, Heimer L, Zaborszky L (1993). Silver staining as a tool for neurotoxic assessment. In: *Assessing Neurotoxicity of Drugs of Abuse*, Erinoff L (ed). National Institute of Drug Abuse Monograph 136, Rockville, Maryland, pp 101-126.
- Bielschowsky M (1904). Silberimpregnation der neurofibrillen. *J Psychol Neurol* 3: 169-188.
- Black MM, Ansley HR (1966). Histone specificity revealed by ammoniacal silver staining. *J Histochem Cytochem* 14(2): 177-181.
- Blackstad TW, Heimer L, Magnaini E (1981). Experimental neuroanatomy: General approaches and laboratory procedures. In: *Neuroanatomical Tract-Tracing Methods*, Heimer L, Robards MJ (eds). Plenum, New York, pp 1-53.
- Breslow E (1973). Metal-protein complexes. In: *Inorganic Biochemistry*, Eichhorn GL (ed). Elsevier, Amsterdam, The Netherlands, pp 227-249.
- Campbell SK, Switzer RC III, Martin TL (1987). Alzheimer's plaques and tangles: Control of silver staining through physical development. *Neuroscience* 13: 678 (abstract).
- Corso T, Neafsey EL, Collins M (1992). Ethanol-induced degeneration of dentate gyrus, entorhinal cortex and other olfactory related areas in rats: Effects of co-administration of MK-801, DNQX, or nimodipine. *Soc Neurosci Abstr* 18: 540.
- Danscher G (1981). Histochemical demonstration of heavy metals: A revised version of the sulphide silver method suitable for both light and electron microscopy. *Histochemistry* 71: 1-16.
- Danscher G, Stoltenberg M, Juhl S (1994). How to detect gold, silver and mercury in human brain and other tissues by autometallographic silver amplification. *Neuropathol Appl Neurobiol* 20: 454-467.
- Dawson RMC, Elliott DC, Elliot WH, Jones KM (1969). Methods for the detection of biochemical compounds on paper and thin layer chromatograms, with some notes on separation. In: *Data for Biochemical Research*, Oxford University Press, New York, pp 509-591.
- de Olmos JD, Beltramino CA, de Olmos-de Lorenzo S (1994). Use of an amino-cupric-silver technique for the detection of early and semiacute neuronal degeneration caused by neurotoxins, hypoxia, and physical trauma. *Neurotoxicol Teratol* 16: 545-561.
- de Olmos JS (1969). A cupric-silver method for impregnation of terminal axon degeneration and its further use in staining granular argyrophilic neurons. *Brain Behav Evol* 2: 213-237.
- de Olmos JS, Ebbesson SOE, Heimer L (1981). Silver methods for the impregnation of degenerating axoplasm. In: *Neuroanatomical Tract-Tracing Methods*, Heimer L, Robards MJ (eds). Plenum, New York, pp 117-170.
- de Olmos JS, Ingram WR (1972). An improved cupric-silver method for impregnation of axonal and terminal degeneration. *Brain Res* 33: 523-529.
- Desclin JC, Escubi J (1974). Effects of 3-acetylpyridine on the central nervous system of the rat, as demonstrated by silver methods. *Brain Res* 77: 349-364.
- Ebbesson SOE (1970). The selective silver-impregnation of degenerating axons and their synaptic endings in nonmammalian species. In: *Contemporary Research Methods in Neuroanatomy*, Nauta WJH, Ebbesson SOE (eds). Springer-Verlag, Berlin, pp 132-162.
- Ellison G (1992). Continuous amphetamine and cocaine have similar neurotoxic effects in lateral habenular nucleus and fasciculus retroflexus. *Brain Res* 598: 353-356.
- Ellison G, Switzer RC III (1993). Dissimilar patterns of degeneration.

FIGURE 7.—Comparisons of silver degeneration staining with standard Nissl or H&E staining. A-D) 40- μ freeze-cut sections. E-F) 30- μ freeze-cut sections. A and B) The medial frontal cortex of a soman-intoxicated rat displays abundant amino cupric silver-stained degenerated cell bodies distributed in layers IV and VI (shown in A), but this level of damage is not evident in the adjacent section, which was stained with thionine-Nissl. Since the affected neurons are somewhat dispersed and are not concentrated, features of these cells that might be revealed by the Nissl stain are not readily apparent. C and D) The olfactory cortex of this rat displays fulminant degeneration on the second day following transection of the olfactory bulb, as displayed in the cupric silver-stained section in C. In an adjacent section, which was stained with H&E, pyknotic nuclei can be seen at higher magnifications, but not in this view. Under conditions in which slides are scanned at low magnification, the ease with which degeneration can be detected with the silver degeneration methods poses distinct advantages. E and F) Detection of degeneration in unexpected areas. E) This image displays the MPTP-induced degeneration of dopaminergic neurons in the pars compacta of the substantia nigra and in the ventral tegmentum of the C57/Balb c mouse, as revealed by the cupric silver stain of de Olmos. F) The cupric silver stain also reveals degenerating neurons in the nucleus sagulum (an auditory system-related nucleus), which is not dopaminergic in its innervation. This illustrates the advantage of the high signal-to-noise properties of the silver generation stains and thereby their value in detecting neurotoxic effects.

- tion in brain following four different addictive stimulants. *Neuroreport* 5: 17–20.
22. Escourrolle R, Poirier J (1978). Basic pathology of the central nervous system. In: *Manual of Basic Neuropathology*, W. B. Saunders Company, Philadelphia, Pennsylvania, pp 1–17.
 23. Fink RP, Heimer L (1967). Two methods for selective silver impregnation of degenerating axons and their synaptic endings in the central nervous system. *Brain Res* 4: 369–374.
 24. Fix AS, Ross JR, Stitzel SR, Switzer RC (1996). Integrated evaluation of central nervous system lesions: Stains for neurons, astrocytes, and microglia reveal the spatial and temporal features of MK-801-induced neuronal necrosis in the rat cerebral cortex. *Toxicol Pathol* 24: 291–304.
 25. Freeman HC (1973). Metal complexes of amino acid and peptides. In: *Inorganic Biochemistry*, Eichhorn GL (ed). Elsevier, Amsterdam, The Netherlands, pp 121–166.
 26. Gallyas F (1982). Physico-chemical mechanism of the argyrophil III reaction. *Histochemistry* 74: 409–421.
 27. Gallyas F, Wolff JR, Bottcher H, Zaborszky L (1980). A reliable and sensitive method to locate terminal degeneration and lysosomes in the CNS. *Stain Technol* 55: 299–306.
 28. Gallyas F, Wolff JR, Bottcher H, Zaborszky L (1980). Selective demonstration of axonal degeneration. *Stain Technol* 55: 291–297.
 29. Gallyas F, Zaborszky L, Wolff JR (1980). Experiments on the mechanism of impregnation methods demonstrating axonal and terminal degeneration. *Stain Technol* 55: 281–290.
 30. Gallyas G, Hsu M, Buzsaki G (1993). Four modified silver methods for thick sections of formaldehyde-fixed mammalian central nervous tissue: 'Dark' neurons, perikarya of all neurons, microglial cells and capillaries. *J Neurosci Methods* 50: 159–164.
 31. Glees P (1946). Terminal degeneration within the central nervous system as studied by a new silver method. *J Neuropathol Exp Neurol* 5: 54–59.
 32. Goodpasture C, Bloom SE (1975). Visualization of nucleolar organizer regions in mammalian chromosomes using silver staining. *Chromosoma* 53: 37–50.
 33. Grafe MR, Leonard CM (1980). Successful silver impregnation of degenerating axons after long survivals in the human brain. *J Neuropathol Exp Neurol* 39: 555–574.
 34. Grant G (1970). Neuronal changes central to the site of axon transection: A method for the identification of retrograde changes in perikarya, dendrites and axons by silver impregnation. In: *Contemporary Research Methods in Neuroanatomy*, Nauta WJH, Ebbesson SOE (eds). Springer-Verlag, Berlin, pp 173–185.
 35. Hedreen JC, Chalmers JP (1972). Neuronal degeneration in rat brain induced by 6-hydroxydopamine: A histological and biochemical study. *Brain Res* 47: 1–36.
 36. Heimer L (1970). Selective silver-impregnation of degenerating axoplasm. In: *Contemporary Research Methods in Neuroanatomy*, Nauta WJH, Ebbesson SOE (eds). Springer-Verlag, Berlin, pp 106–131.
 37. Heimer L, Kalil R (1978). Rapid transneuronal degeneration and death of cortical neurons following removal of the olfactory bulb in adult rats. *J Comp Neurol* 178: 559–609.
 38. Heimer L, Peters A (1968). An electron microscope study of a silver stain for degenerating boutons. *Brain Res* 8: 337–346.
 39. Howell WM, Denton TE, Diamond JR (1975). Differential staining of the satellite regions of human acrocentric chromosomes. *Experientia* 31: 260–262.
 40. Humason GL (1972). Gomori methenamine-silver nitrate method (Grocott adaptation, 1955; Mowry modification, 1959). In: *Animal Tissue Techniques*, Kennedy D, Park RB (eds). W. H. Freeman and Company, San Francisco, pp 397–399.
 41. Humason GL (1972). Silver impregnating II: Bodian method. In: *Animal Tissue Techniques*, D Kennedy, Park RB (eds). W. H. Freeman and Company, San Francisco, pp 227–229.
 42. Illis LS, Mitchell J (1970). The effect of tetanus toxin on boutons terminaux. *Brain Res* 18: 283–295.
 43. Jancso G, Kiraly E (1980). Distribution of chemosensitive primary sensory afferents in the central nervous system of the rat. *J Comp Neurol* 190: 781–792.
 44. Janssen R, Schweitzer L, Jensen KF (1991). Glutamate neurotoxicity in the developing rat cochlea: Physiological and morphological approaches. *Brain Res* 552: 255–264.
 45. Jarrard LE (1989). On the use of ibotenic acid to lesion selectively different components of the hippocampal formation. *J Neurosci Methods* 29: 251–259.
 46. Jensen KF, Miller DB, Olin JK, O'Callaghan JP (1990). Evidence for the neurotoxicity of methylenedioxymethamphetamine (MDMA) using a cupric-silver stain for neuronal degeneration. *Soc Neuroscience* 16: 256.
 47. John DHO, Field GTJ (1963). In: *Photographic Chemistry*, Reinhold, New York, p 93, Figure 14.
 48. Khurgel M, Switzer RC III, Teskey GC, Spiller AE, Racine RJ, Ivy GO (1995). Activation of astrocytes during epileptogenesis in the absence of neuronal degeneration. *Neurobiol Dis* 2: 23–35.
 49. Leonard C (1979). Degeneration methods in neurobiology. *Trends Neurosci* 1: 156–159.
 50. Leonard C (1981). Silver degeneration methods. In: *Current Trends in Morphological Techniques*, Johnson JE Jr (ed). CRC Press, Boca Raton, Florida, pp 93–140.
 51. Levi-Montalcini R, Aloe L (1981). Mechanism(s) of action of nerve growth factor in intact and lethally injured sympathetic nerve cells in neonatal rodents. In: *Cell Death in Biology and Pathology*, Bowen ID, Lockshin RA (eds). Chapman and Hall, London, pp 295–328.
 52. Levin S, Bucci TJ, Cohen SM, Fix AS, Hardisty JF, LeGrand EK, Maronpot RR, Trump BF (1999). The nomenclature of cell death: Recommendations of an ad hoc committee of the Society of Toxicologic Pathologists. *Toxicol Pathol* 27: 484–490.
 53. Liesegang RE (1911). Die kolloid-chemie der histologischen silberfärbung. *Kolloid Beitr* 3: 1–46.
 54. Likovsky Z, Smetana K (1981). Further studies on the cytochemistry of the standardized silver staining of interphase nucleoli in smear preparations of Yoshida ascitic sarcoma cells in rats. *Histochemistry*, 72: 301–313.
 55. Lockshin RA (1999). Commentary: The utility of apoptosis terminology. *Toxicol Pathol* 24: 492–493.
 56. Miller PJ, Zaborszky L (1997). 3-Nitropropionic acid neurotoxicity: Visualization by silver staining and implications for use as an animal model of Huntington's disease. *Exp Neurol* 146: 212–229.
 57. Myer J, Ellison G (1999). Mapping the neuronal degeneration in new-born rat pups using silver stains. *Soc Neurosci Abstr* 25: 1776.
 58. Naoumenko J, Feigin I (1974). A simple silver solution for staining reticulins. *Stain Technol* 49: 153–155.
 59. Nauta WJH, Gyax PA (1951). Silver impregnation of degenerating axon terminals in the central nervous system (1) Technic (2) Chemical notes. *Stain Technol* 26: 5–11.
 60. O'Callaghan JP, Jensen KF (1992). Enhanced expression of glial fibrillary acidic protein and the cupric silver degeneration reaction can be used as sensitive and early indicators of neurotoxicity. *Neurotoxicology* 13: 113–122.
 61. Ofner D, Aubele M, Biesterfeld S, Derenzini M, Gimenez-Mas JA, Hufnagl P, Ploton D, Trere D, Ruschoff J (1995). Guidelines of AgNOR quantitation—First update. *Virchows Arch* 427: 341.
 62. Peng YG, Taylor TB, Finch RE, Switzer RC, Ramsdell JS (1994). Neuroexcitatory and neurotoxic actions of the amnesic shellfish poison, domoic acid. *Neuroreport* 5: 981–985.
 63. Peters A (1955). Experiments on the mechanism of the silver staining. Part I. Impregnation. *J Microsc Sci* 96: 84–102.
 64. Peters A (1955). Experiments on the mechanism of the silver staining. Part II. Development. *J Microsc Sci* 96: 103–115.
 65. Peters A (1955). Experiments on the mechanism of the silver staining. Part III. Quantitative studies. *J Microsc Sci* 96: 301–316.
 66. Petras JM (1981). Soman neurotoxicity. *Fundam Appl Toxicol* 1: 242.
 67. Ricaurte GA, Guillery RW, Seiden LS, Schuster CR, Moore RY (1982). Dopamine nerve terminal degeneration produced by high doses of methamphetamine in the rat brain. *Brain Res* 235: 93–103.
 68. Shepherd GM (1991). *Foundations of the Neuron Doctrine*. Oxford

- University Press, New York. Fidia Research Foundation, (ed). *History of Neuroscience*. No. 6.
69. Switzer RC (1980). Toxicity of oxygen in iron-rich areas of rat brain. *Soc Neurosci Abstr* 6: 738.
70. Switzer RC, Campbell SK (1987). MPTP induces degeneration in nucleus sagulum, thalamus, dorsal raphe and of non-cortical projecting dopaminergic brainstem neurons. *Soc Neurosci Abstr* 13: 247.
71. Switzer RC, Campbell SK, Murdock TM (1993). A histologic method for staining Alzheimer pathology. US Patent 5192688.
72. Switzer RC, Majchrowicz E, Weight FW (1982). Ethanol induced argyrophilia in neurons of entorhinal cortex of rat. *Anat Rec Abstr*
73. Switzer RC, Murphy MR, Campbell SK, Kerenyi SZ, Miller SA, Hartgraves SL (1988). Soman in multiple low doses: Damage to selected populations of neurons in rat brain. *Soc Neurosci Abstr* 14: 774.
74. Switzer RC III (1976). Neural argyrophilia induced by puromycin: A directed Golgi-like method. *Neurosci Lett* 2: 301-305.
75. Switzer RC III (1991). Strategies for assessing neurotoxicity. *Neurosci Biobehav Rev* 15: 89-93.
76. Switzer RC III (1993). Silver staining methods: Their role in detecting neurotoxicity. In: *Markers of Neuronal Injury and Degeneration*, Vol 679, Johannessen JN (ed). Annals of the New York Academy of Sciences, New York, pp 341-348.
77. Switzer RC III, Bogo V, Mickley GA (1994). Histologic effects of high energy electron and proton irradiation of rat brain detected with a silver-degeneration stain. *Adv Space Res* 14: 443-451.
78. Switzer RC III, Merrill CR, Shjifrin S (1979). A highly sensitive silver stain for detecting proteins and peptides in polyacrylamide gels. *Anal Biochem* 98: 231-237.
79. Switzer RC III, Wheat DL, Turner JC, Baker CA (1999). Patterns of programmed cell death in rat brain nuclei during postnatal days 1-10 as revealed with a silver degeneration stain. *Soc Neurosci Abstr* 25: 1776.
80. Tanaka D Jr, Bursian SJ (1989). Degeneration patterns in the chicken central nervous system induced by ingestion of the organophosphorus delayed neurotoxin tri-ortho-tolyl phosphate: A silver impregnation study. *Brain Res* 484: 240-256.
81. Tanaka D Jr, Bursian SJ, Lehning EJ, Aulerich RJ (1990). Exposure to triphenyl phosphite results in widespread degeneration in the mammalian central nervous system. *Brain Res* 531: 294-298.
82. Waller AV (1850). Experiments on the section of the glossopharyngeal and hypoglossal nerves of the frog, and observations of the alterations produced thereby in the structure of their primitive fibers. *Philos Trans R Soc Lond (Biol)* 140: 423-469.
83. Yamamoto T, Iwasaki Y, Konno H, Ilzuka H (1986). Identification of cells undergoing physiological neuronal death in the neonatal rat brain by the Fink-Heimer method. *Brain Res* 374: 419-424.